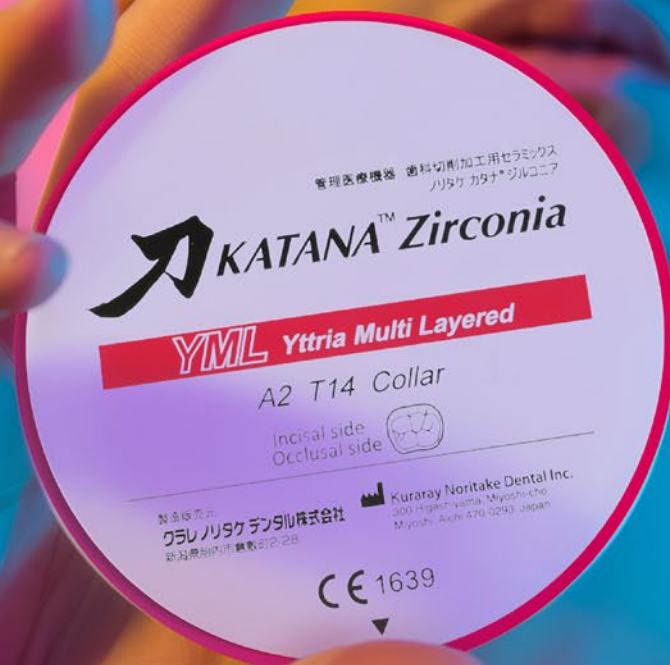

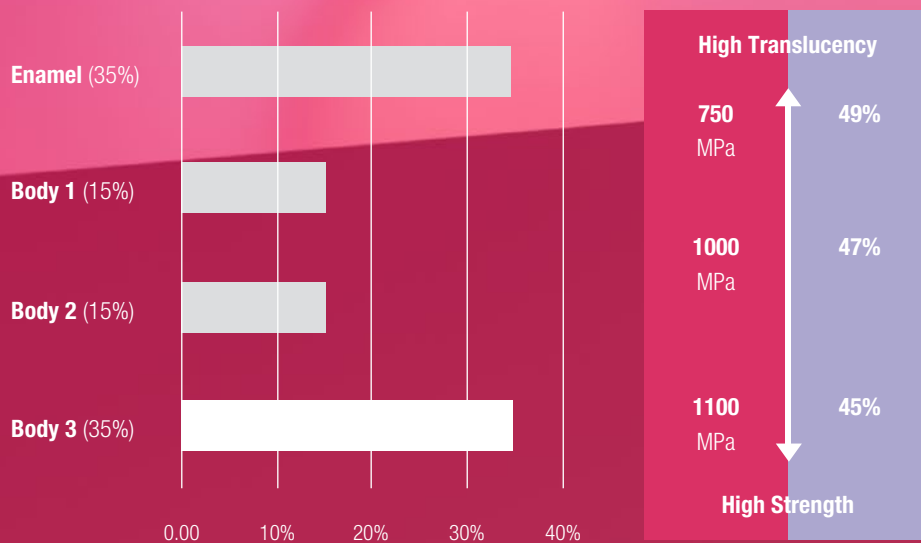
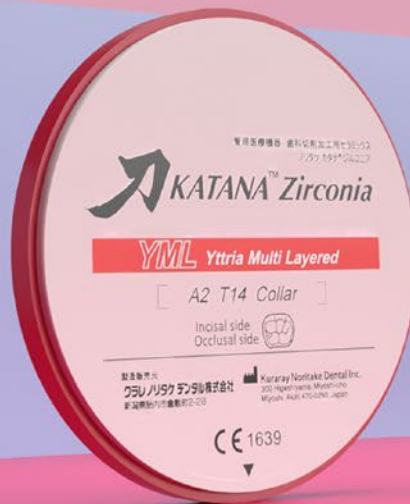CLINICAL CASES

With KATANA™ Zirconia YML



REVOLUTIONARY ALL-IN-ONE DISC DESIGN

KATANATM Zirconia YML is a new definition of zirconia in dentistry. Characterized by a unique raw material combination of highly translucent zirconia with high strength, this innovative material will truly empower your dental lab. See how it can help you bring more efficiency, clarity, simplicity and precision into your procedures without compromising the quality of the outcomes!



(..%) the thickness of each layer in a disc in %

Measurement condition: Evaluated by base material (white color).
 1. According to ISO 6872: 2015, Sample size: 3 x 4 x 40mm,
 2. All light transmittance, illuminant: D65, Thickness of sample: 1.0mm

Data source: Kuraray Noritake Dental Inc.
 The numerical value varies according to a condition.

CLINICAL CASES

KATANA™ Zirconia YML

- | | | | |
|----|--|----|--|
| 4 | AESTHETIC MONOLITHIC
LONG-SPAN RESTORATIONS
Clinical Case by MDT Daniele Rondoni | 22 | COSMETIC CAMOUFLAGE
FOR A PATIENT WITH
PERIODONTAL DISEASES
Clinical Case by DT Giuliano Moustakis |
| 7 | HIGHLY AESTHETIC ZIRCONIA:
INDIVIDUALISATION OPTIONS
Clinical Case by MDT Leonidas Dimitriou | 26 | COMPLEX REHABILITATION
PROCEDURE IN THE MAXILLA
Clinical Case by Marco Valenti, DDS
and CDT Angelo Canale |
| 10 | PRODUCTION OF A FULL-
CONTOUR SCREW-RETAINED
IMPLANT BRIDGE
Clinical Case by MDT Daniele Rondoni
and MDT Roberto Rossi | 30 | TREATMENT OF A YOUNG
PATIENT WITH ZIRCONIA
VENEERS
Clinical Case by MDT Daniele Rondoni
and Dr. Enzo Attanasio |
| 12 | MAXIMUM AESTHETICS
IN MODERN ZIRCONIA
REHABILITATIONS
Clinical Case by DT Simone Maffei
and Dr. Filippo Menini | | |
| 17 | A NEW SMILE WITH ONLY
4 ZIRCONIA CROWNS
Clinical Case by DT Kanstantsin Vyshamirski | | |



AESTHETIC MONOLITHIC LONG-SPAN RESTORATIONS

Clinical Case by MDT Daniele Rondoni

What is possible with KATANA™ Zirconia YML from Kuraray Noritake Dental Inc.? The following clinical case was one of the first we treated with the innovative multi-layered material - and it reveals its aesthetic potential.

Clinical Case 1

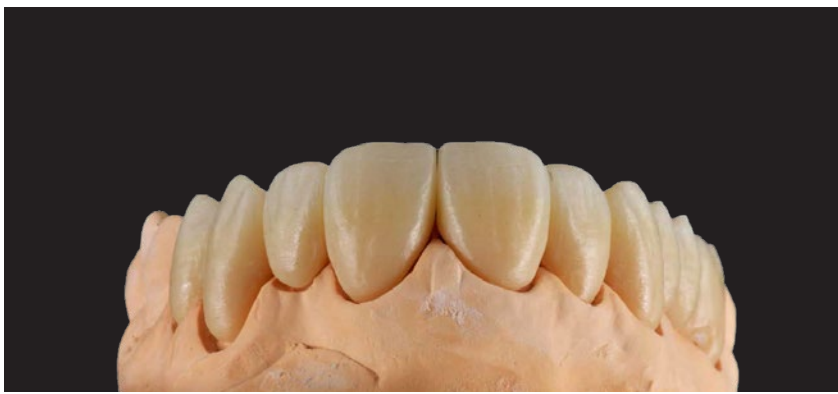

FIG. 01 KATANA™ Zirconia YML 4-unit and 6-unit bridges after milling and sintering. A natural vestibular surface texture plays a decisive role in the creation of aesthetic monolithic restorations.

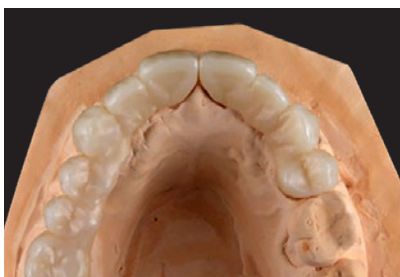

FIG. 02 Occlusal view of the two monolithic bridges. The lingual surface design facilitates oral hygiene procedures.

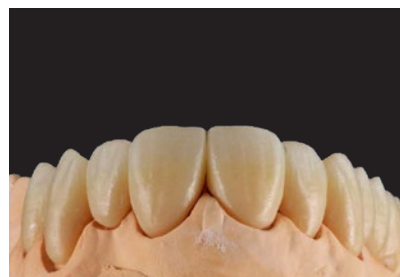


FIG. 03 A light source behind the restorations reveals the incisal translucency.

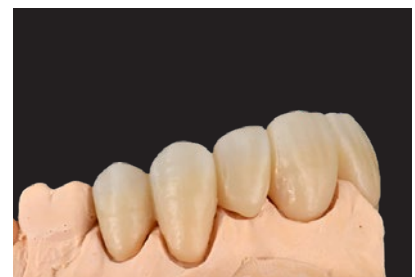

FIG. 04 Buccal view of the 4-unit bridge.

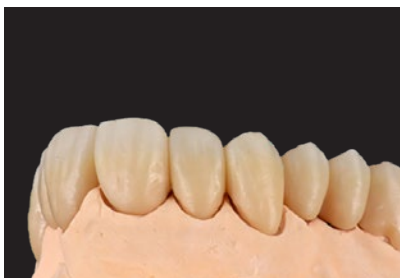

FIG. 05 Buccal view of the 6-unit bridge.

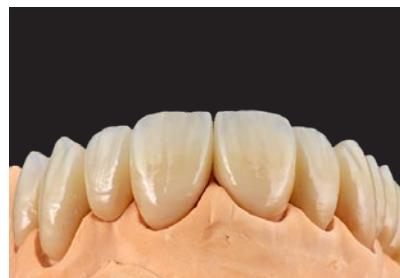

FIG. 06 Frontal view of the two bridges on the model after ultra-micro layering with CERABIEN™ ZR FC Paste Stain (Kuraray Noritake Dental Inc.).

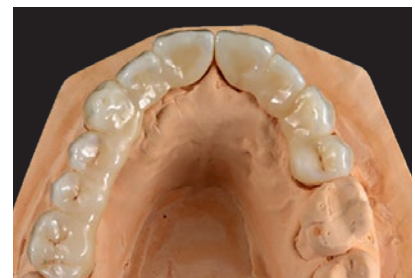

FIG. 07 Occlusal view of the stained and glazed restorations.

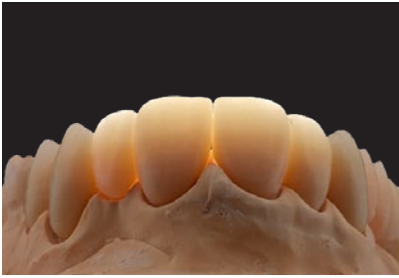

FIG. 08 Stained and glazed restorations and their translucency in transmitted light.

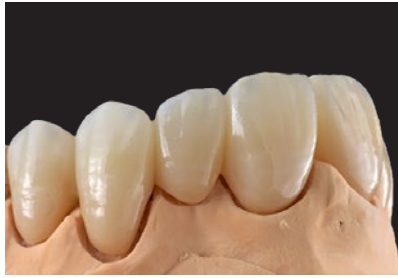

FIG. 09 Buccal view of the finished 4-unit bridge.

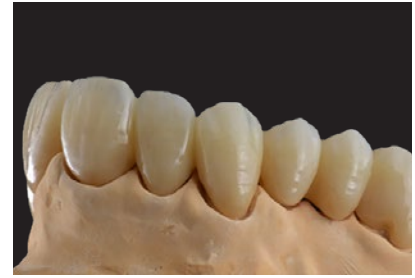

FIG. 10 Occlusal view of the two monolithic bridges. The lingual surface design facilitates oral hygiene procedures.

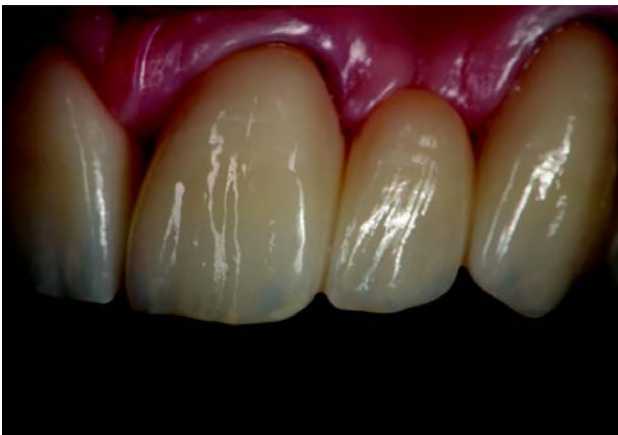

FIG. 11 Buccal view of the 6-unit bridge cemented in the patient's mouth.

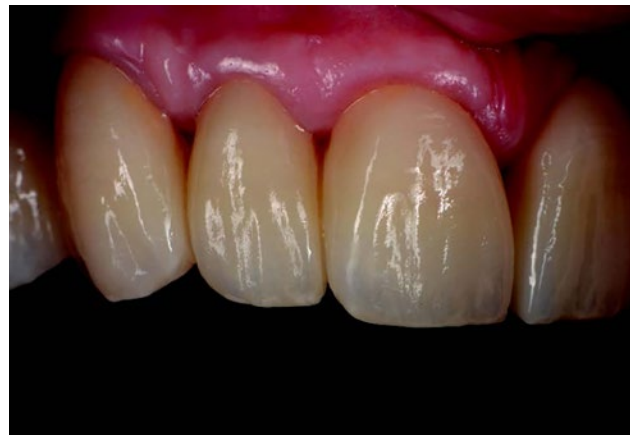
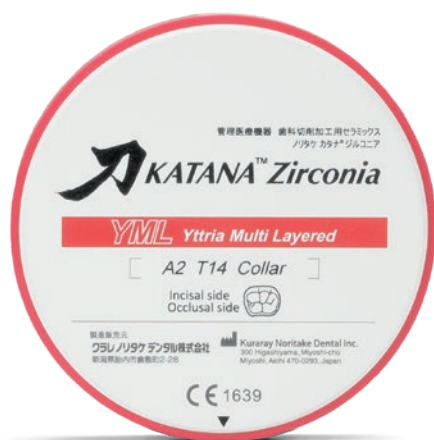
FIG. 12 Buccal view of the 4-unit bridge cemented in the patient's mouth.



KATANA™ Zirconia YML

ACHIEVE
MAXIMUM
AESTHETIC
RESULTS

A portrait of a middle-aged man with short, graying hair, wearing a dark suit jacket over a light blue shirt. The portrait is set against a background that transitions from dark blue on the left to a bright pink on the right. A large, thin white circle is overlaid on the image, partially framing the man's face. The text 'HIGHLY AESTHETIC ZIRCONIA: INDIVIDUALISATION OPTIONS' is written in large, white, sans-serif capital letters across the lower half of the image.

HIGHLY AESTHETIC ZIRCONIA: INDIVIDUALISATION OPTIONS

Clinical Case by MDT Leonidas Dimitriou

As an addition to its well-aligned portfolio of multi-layered zirconia (KATANA™ Zirconia Multi-Layered series) and veneering porcelain for zirconia (CERABIEN™ ZR), Kuraray Noritake Dental Inc. has recently introduced a set of dyeing liquids. Esthetic Colorant for KATANA™ Zirconia is applied to the surface of the monolithic or anatomically reduced zirconia restoration prior to the final sintering procedure. In this way, it is possible to imitate typical internal colour effects of natural teeth quite easily. Depending on the desired outcome, users may add just a final layer of glaze, liquid ceramics or stains and porcelains to their zirconia restorations treated with Esthetic Colorant. The following two case examples are used to demonstrate two different procedures involving the use of the effect liquids.

Clinical Case 2

CASE EXAMPLE 1

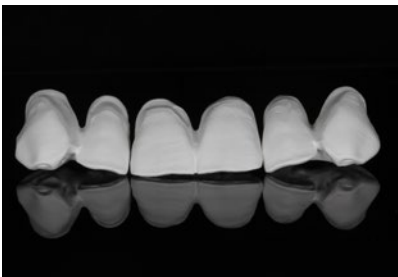

FIG. 01 Pre-sintered anatomically reduced crowns after milling.

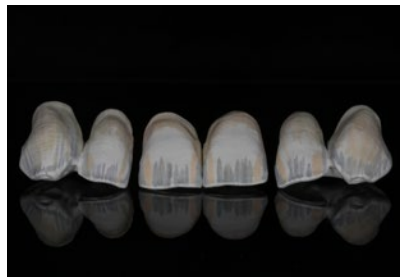

FIG. 02 Esthetic Colorant applied to the milled restorations with the Liquid Brush Pen.

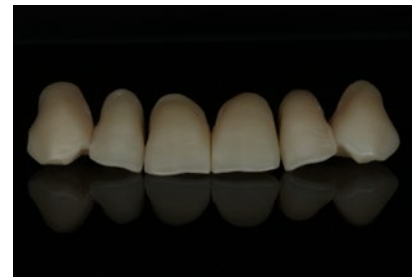

FIG. 03 Appearance of the individualized restorations after drying for half an hour, followed by the final sintering procedure.

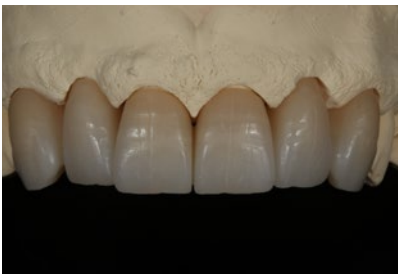

FIG. 04 Restorations after layering with with CERABIEN™ ZR porcelains.

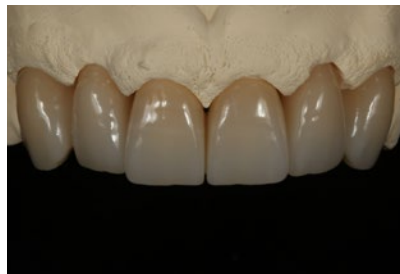

FIG. 05 Final restorations after glazing with CERABIEN™ ZR Paste Stain Glaze.

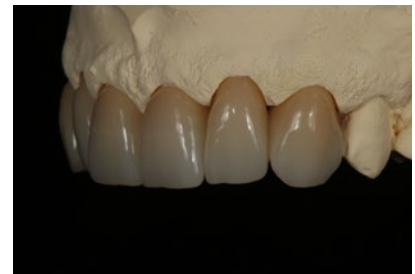

FIG. 06 Lateral view of the final restorations from the left.

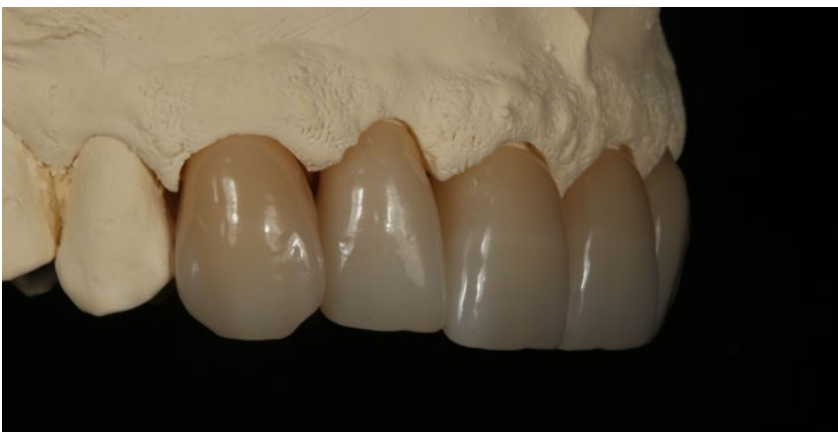

FIG. 07 Lateral view of the final restorations from the right.

CASE EXAMPLE 2

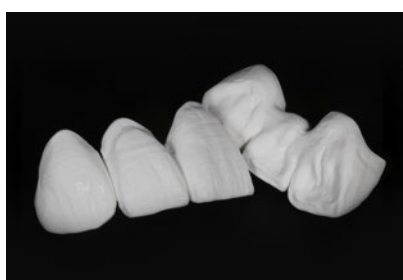

FIG. 08 Milled monolithic restorations (KATANA™ Zirconia YML in the colour A3), reduced with hand instruments by 0.2 mm, with added texture effects.

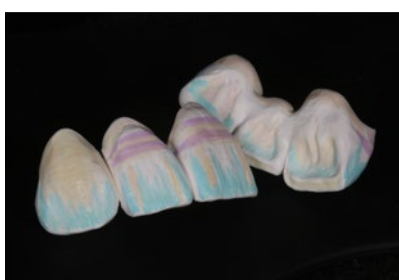

FIG. 09 Vestibular and palatal surfaces individualized with Esthetic Colorant to create and intensify some natural colour effects.

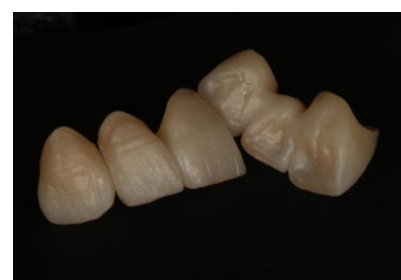

FIG. 10 Appearance of the restorations immediately after sintering.

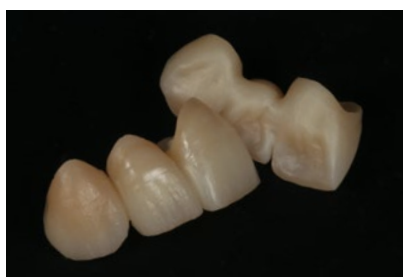


FIG. 11 Restorations after internal staining.

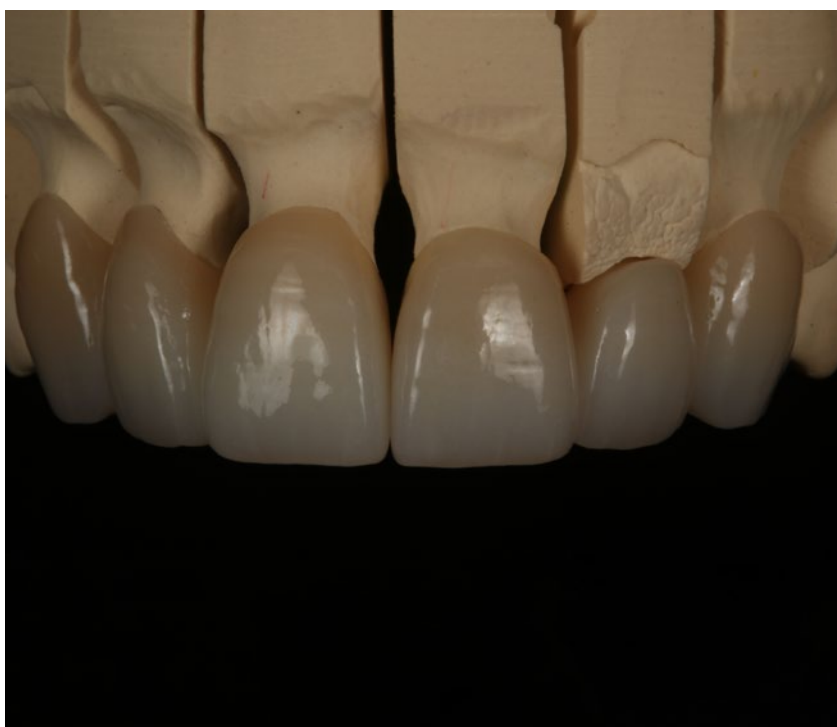

FIG. 13 Final outcome after glazing.

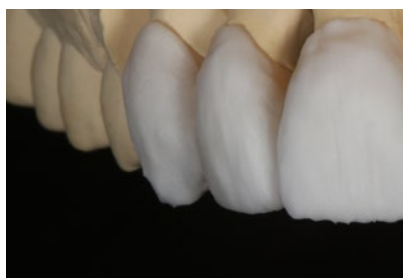

FIG. 12 A layer of CERABIEN™ ZR Luster Porcelain applied to the minimally reduced restorations.



PRODUCTION OF A FULL- CONTOUR SCREW-RETAINED IMPLANT BRIDGE

**Clinical Case by MDT Daniele Rondoni
and MDT Roberto Rossi**

A full-contour screw-retained implant bridge made of zirconia with a titanium bar was planned in this case. The zirconia part was milled from KATANA™ Zirconia YML, the vestibular morphology refined with rotating instruments and then, the vestibular, palatal and occlusal surfaces were treated with Esthetic Colorant.

Clinical Case 3

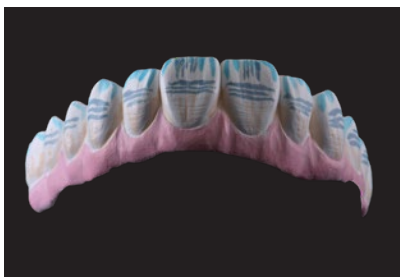

FIG. 01 Occlusal view of the milled zirconia structure after the application of Esthetic Colorant BLUE, GRAY, ORANGE and PINK.

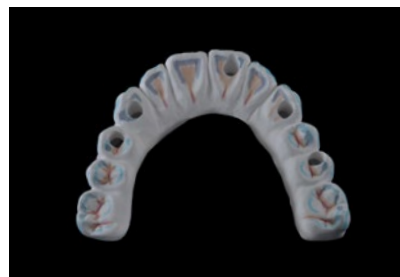


FIG. 02 Occlusal view of the milled zirconia structure after the application of Esthetic Colorant BLUE, GRAY, ORANGE and PINK.

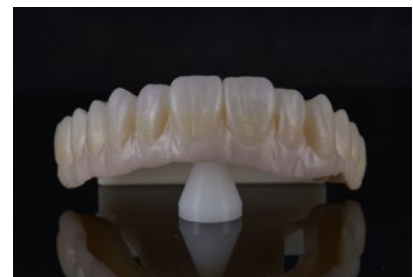

FIG. 03 Nicely pre-treated zirconia structure after sintering.

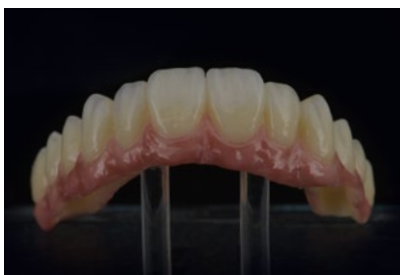

FIG. 04 Frontal view of the finalized zirconia part. The vestibular area and the tissue parts have been treated with CERABIEN™ ZR FC Paste Stain and Glaze.

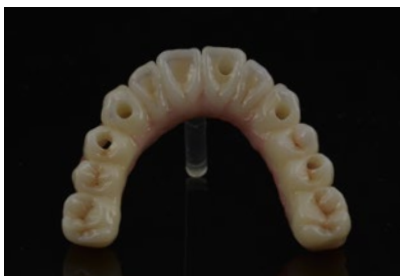

FIG. 05 Occlusal view of the structure after finishing. High-gloss polishing is the preferred finishing approach for the contact areas.

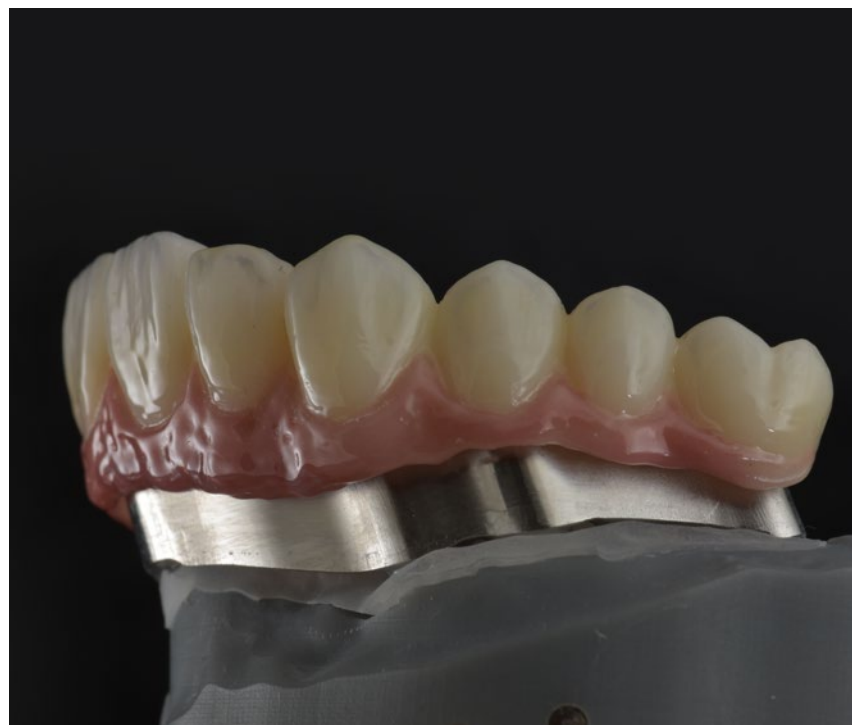

FIG. 06 Connecting the zirconia superstructure and titanium bar.



MAXIMUM AESTHETICS IN MODERN ZIRCONIA REHABILITATIONS

**Clinical Case by DT Simone Maffei
and Dr. Filippo Menini**

The 31-year-old patient presented with multiple carious lesions, inadequate restorations and in particular a destructive caries in the maxillary right second premolar (tooth #15, FDI notation). The latter tooth was endodontically treated and built up using a glass fibre post. The X-ray revealed carious lesions and infiltrated margins of the restorations. The treatment plan for this quadrant included direct composite restorations on the first premolar and first molar (teeth #14 and #16) and an indirect zirconia crown used to restore the second premolar (tooth #15). In addition, a zirconia crown needed to be produced for the mandibular right second premolar (tooth #45).

Clinical Case 4

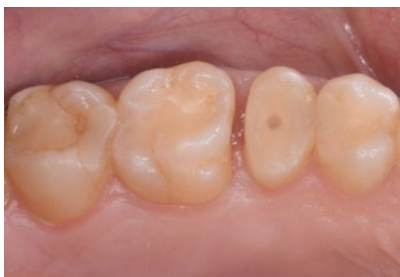

FIG. 01 Initial clinical situation in the maxillary right quadrant.

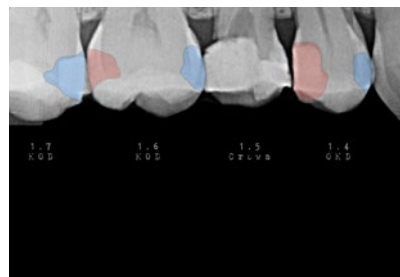


FIG. 02 Radiograph showing carious lesions and restorations with marginal leakage.

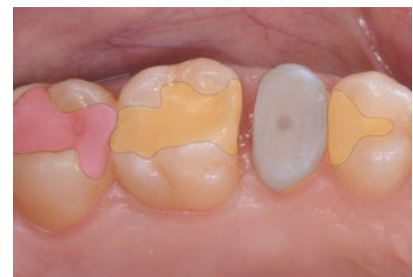

FIG. 03 Marked surfaces to be treated.

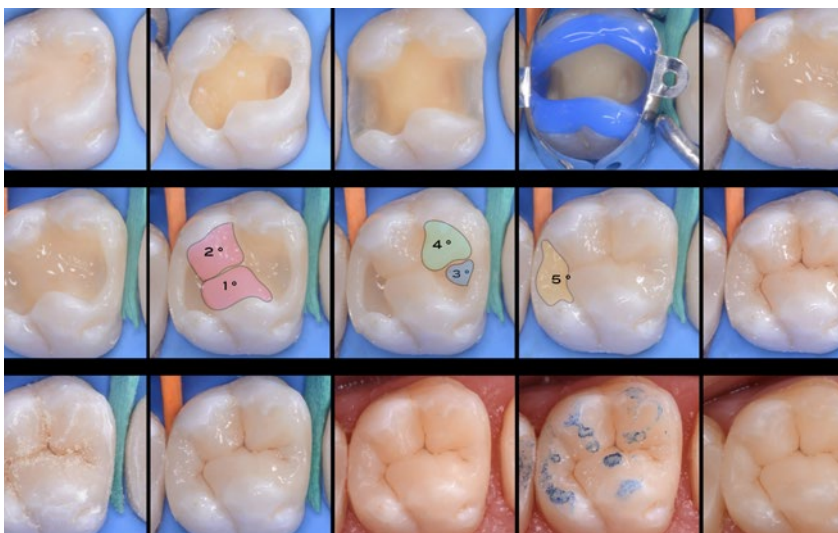

FIG. 04 Restoration procedure on the maxillary first molar.

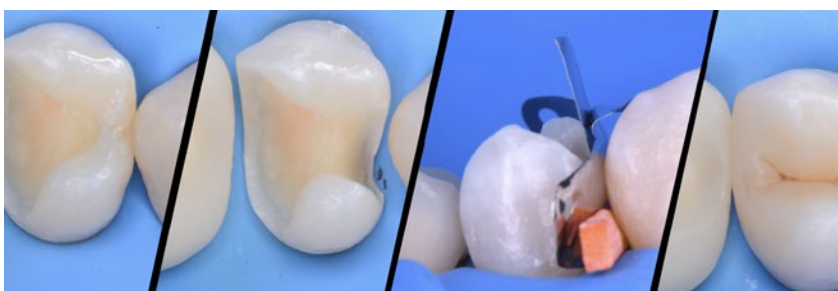

FIG. 05 Restoration procedure on the maxillary first premolar.

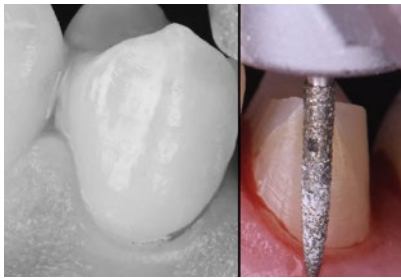


FIG. 06 Crown preparation on the maxillary second premolar. Tooth preparation on this tooth and the mandibular second premolar was performed using the biologically oriented preparation technique.

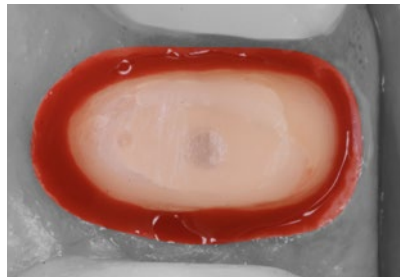


FIG. 07 Subgingival preparation is performed using burs with calibrated notches, ensuring the supra-crestal attachment complex remains untouched and staying within the sulcus width.



FIG. 08 Production of the temporary restoration.

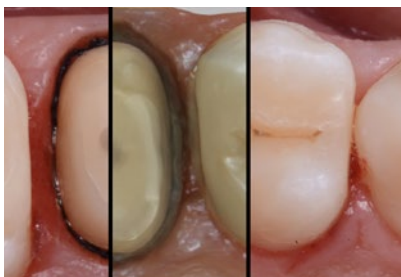


FIG. 09 Digital impression taken using the double cord technique: a 000-sized cord soaked in aluminium chloride is placed in the sulcus as the first cord, followed by a non-soaked cord of size 1.

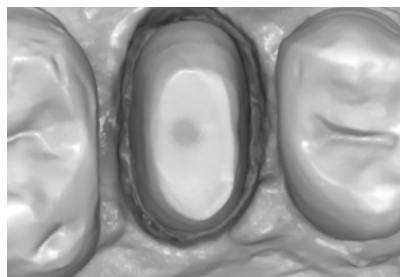


FIG. 10 Greyscale view of the impression, facilitating the clinical evaluation.

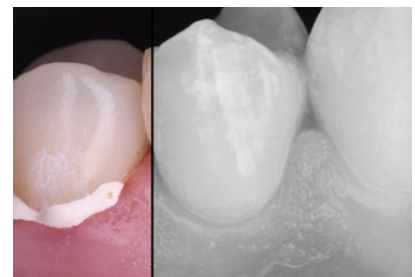

FIG. 11 Cementation of the temporary restoration.

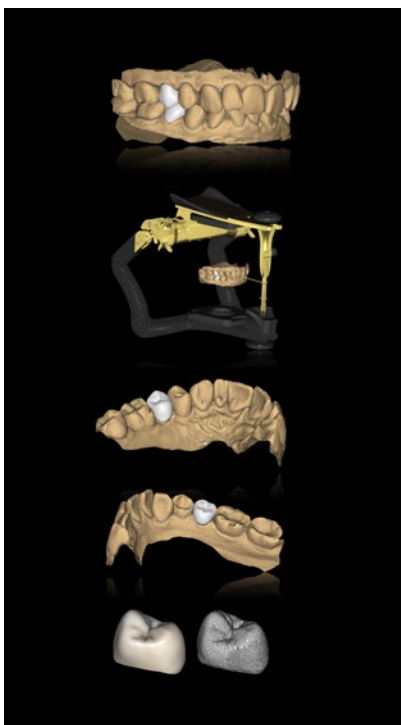


FIG. 12 Virtual models based on the digital impression of both arches, with the software-designed full-contour crowns in different views.



FIG. 13 KATANA™ Zirconia YML blank with milled crowns.

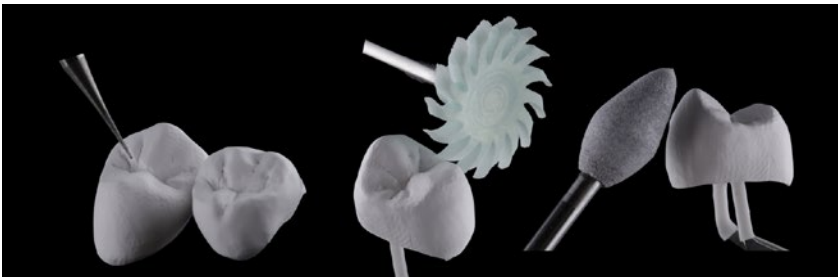


FIG. 14 Finishing with diamond burs and specific rubbers for pre-sintered zirconia.

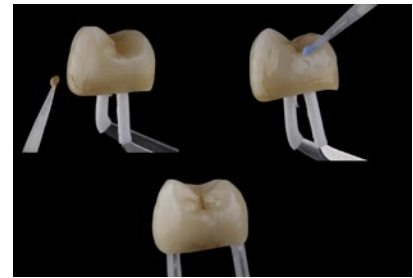

FIG. 15 Characterisation with CERABIEN™ ZR FC Paste Stain.

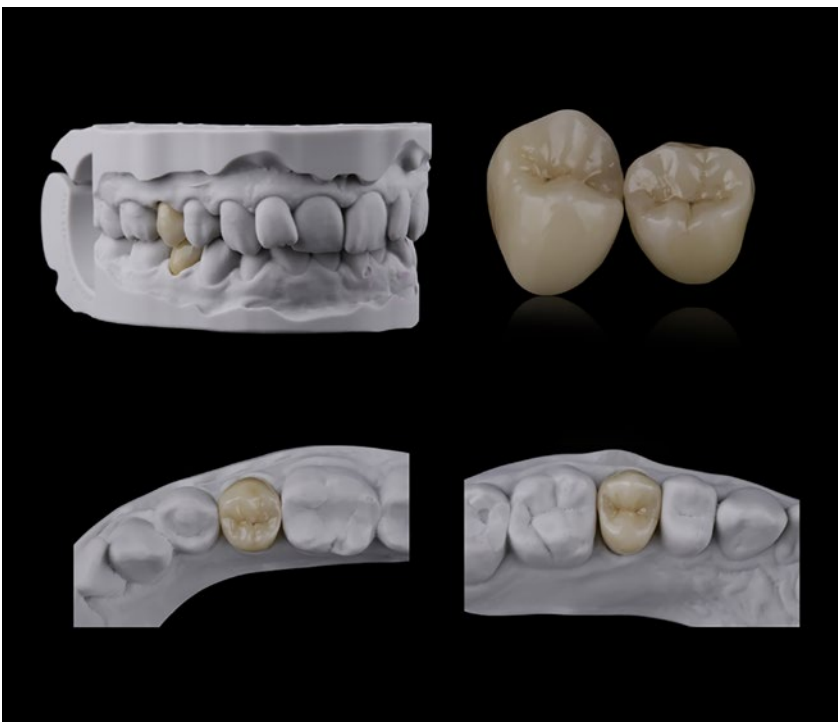

FIG. 16 Finished restorations ready to be handed over to the clinician.

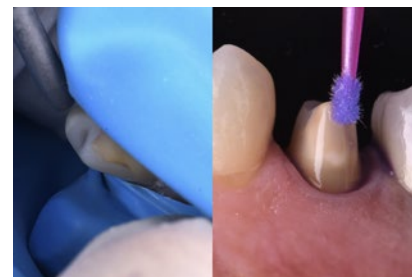


FIG. 17 Cementation procedure in the maxilla: Sandblasting of the tooth and cleaning of the tooth structure with KATANA™ Cleaner.

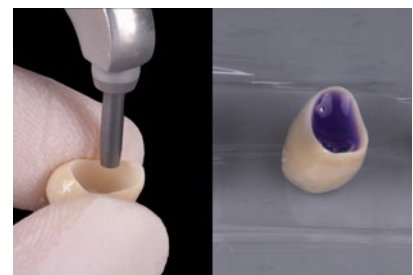


FIG. 18 Cementation procedure in the maxilla: Sandblasting of the crown's intaglio and cleaning of the restoration with KATANA™ Cleaner.

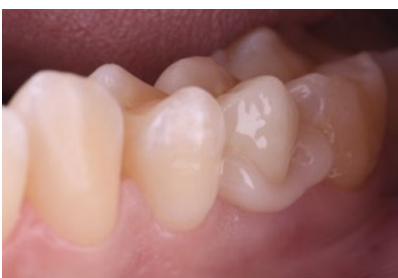

FIG. 19 Cementation procedure in the maxilla: Self-adhesive cementation with PANAVIA™ SA Cement Universal.

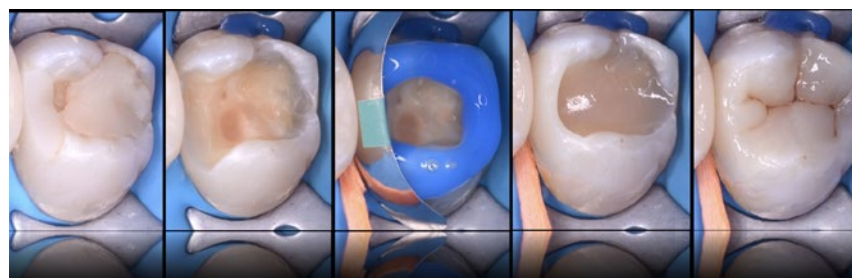


FIG. 20 Direct restoration procedure on the second molar.

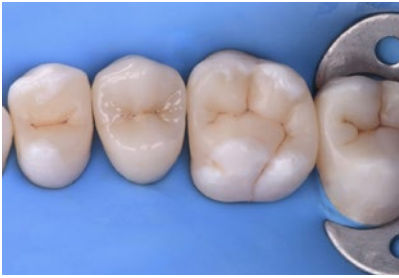

FIG. 21 Restorations immediately after finishing and polishing.

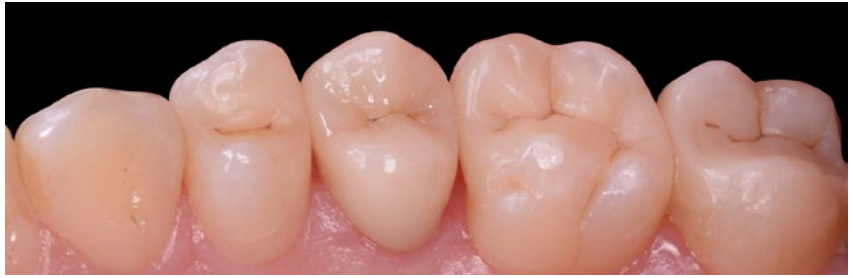

FIG. 22 Detailed view of the restored quadrant.

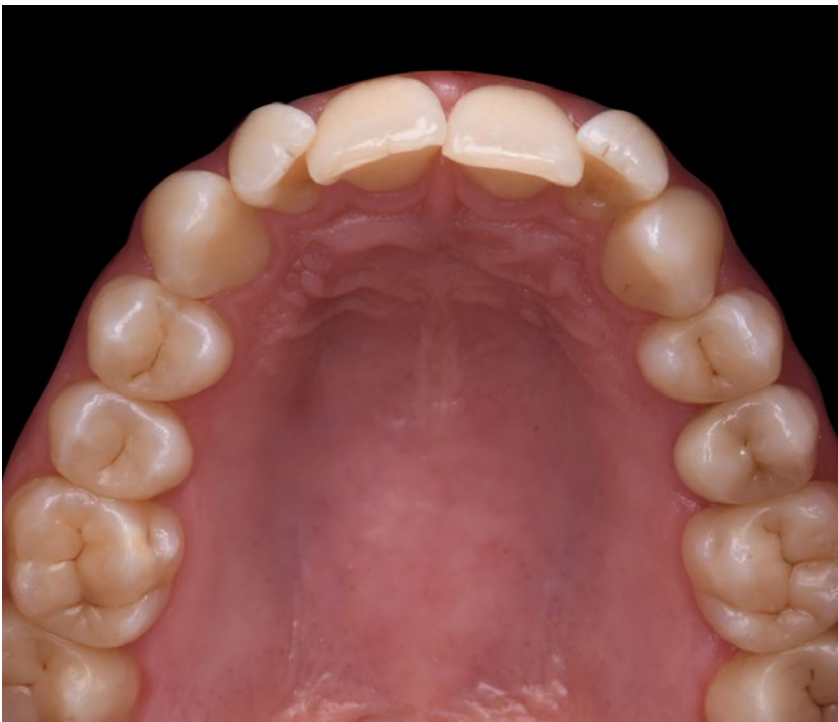

FIG. 23 Occlusal view of the maxillary teeth.



A NEW SMILE WITH ONLY 4 ZIRCONIA CROWNS

Clinical Case by DT Kanstantsin Vyshamirski

A male patient (47 years of age) presented to his dentist with severe damage to his teeth. His main request was to increase aesthetics, to achieve a more pleasing envisaged aesthetic area. A side request was to achieve a 'whitening but natural look'. This was achieved by using a lighter colour palette of zirconia and porcelain materials. The final result was achieved through the creation of a wax-up, followed by a mock-up, provisional restoration and finally adhesive bonding of the zirconia crowns.

Clinical Case 5

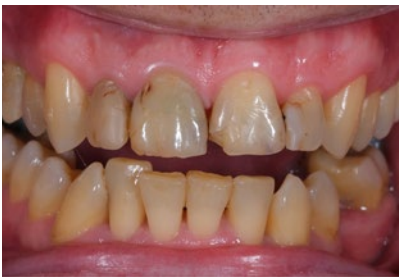

FIG. 01 Initial situation. Male patient (age 47).

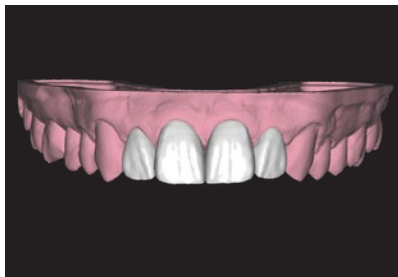


FIG. 02 Planning the new smile according to the patient's aesthetic and functional parameters.

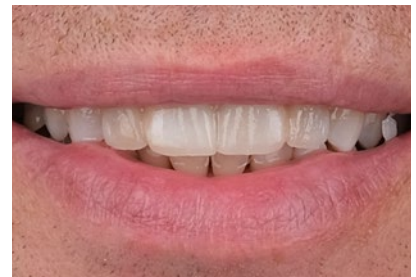

FIG. 03 Mock-up in place to check the new look in the patient's mouth.

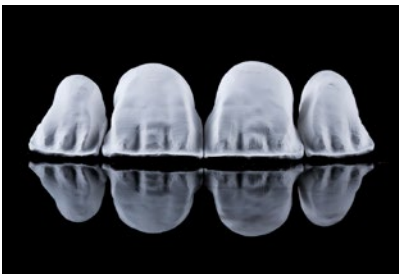

FIG. 04 KATANA™ Zirconia YML shade A1 crowns with labial cutback after milling.

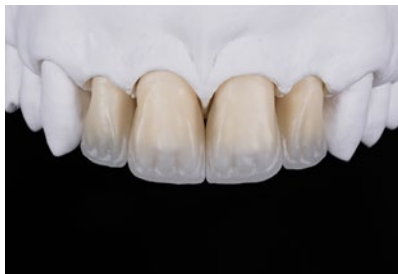


FIG. 05 Crowns after sintering on the plaster model.

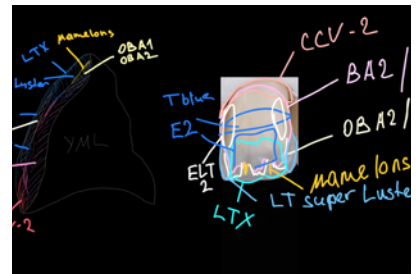


FIG. 06 Noritake CERABIEN™ ZR porcelain layering map.

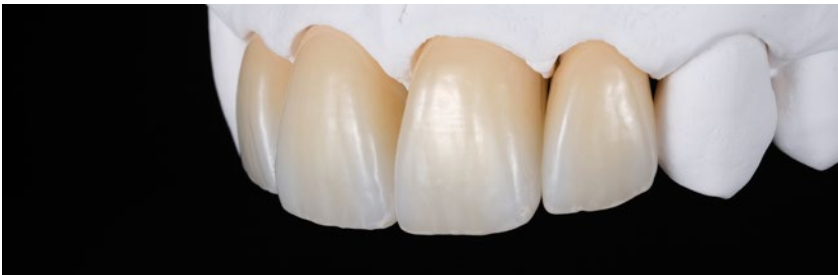

FIG. 07 Finishing the labial surface using both polishing and selfglaze. On the palatal side of the crowns, only CERABIEN™ FC Paste Stain stains and glaze were used for finishing. To aid in optimisation of the soft tissue condition, the palato-cervical and near proximal areas were polished.

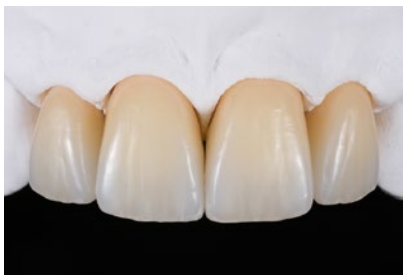

FIG. 08 Finished crowns on the plaster model.

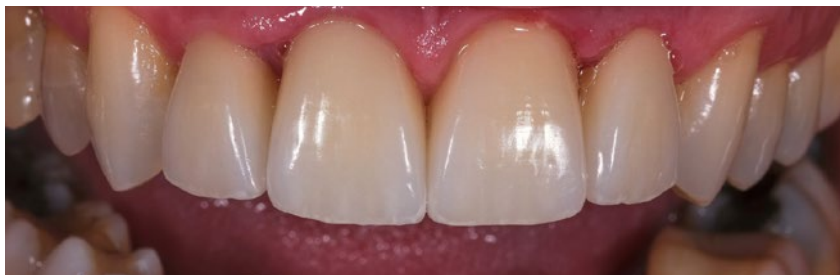

FIG. 09 Try-in using PANA VIA™ V5 White try-in paste, to confirm the proper appearance. For the final adhesive cementation, PANA VIA™ V5 White has been used.

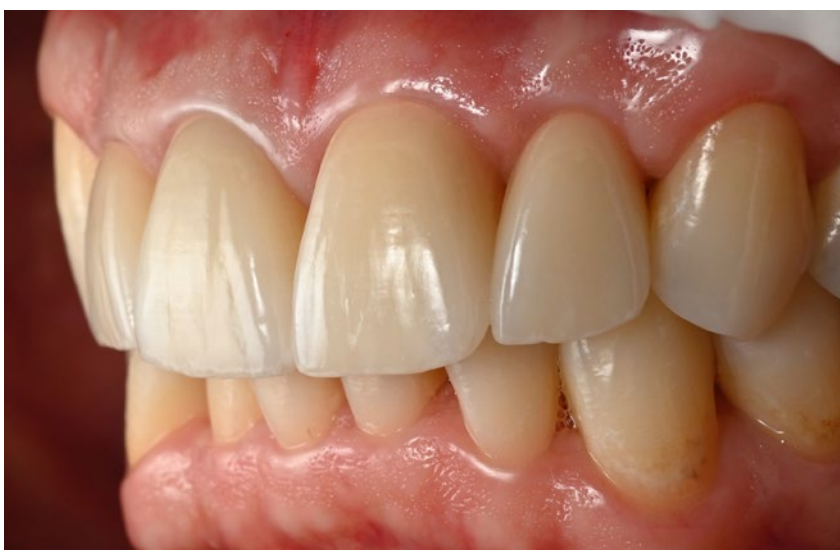

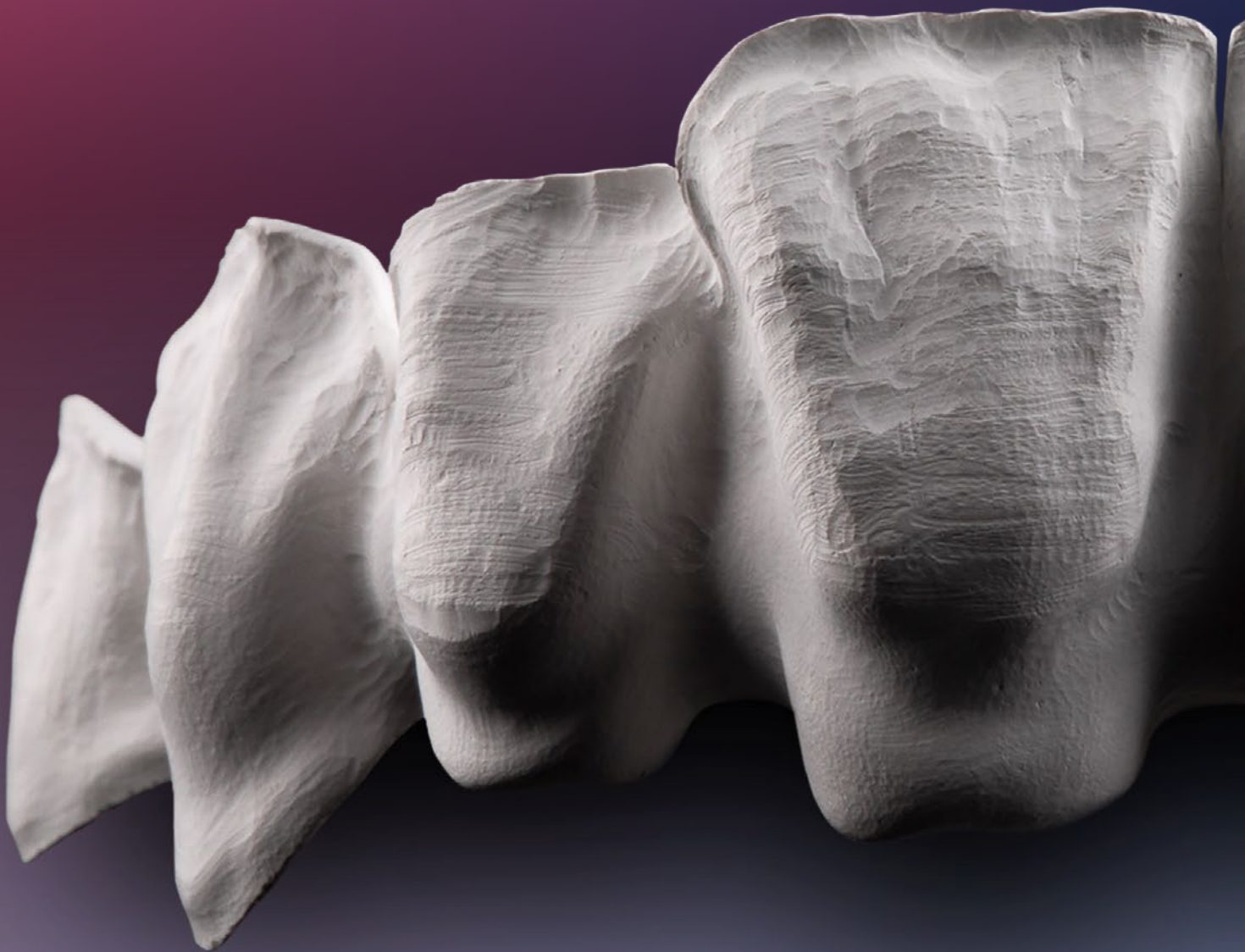
FIG. 10 Situation after seven months. The result is aesthetically pleasing and the gingival condition excellent.

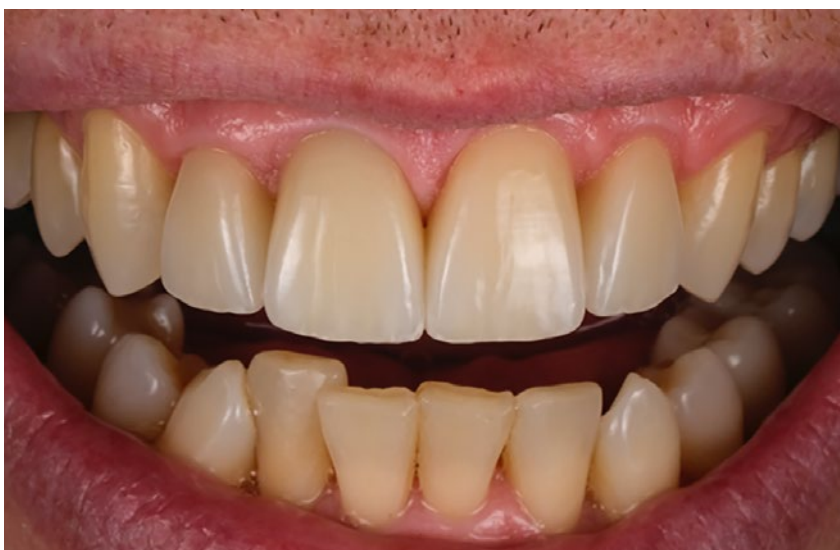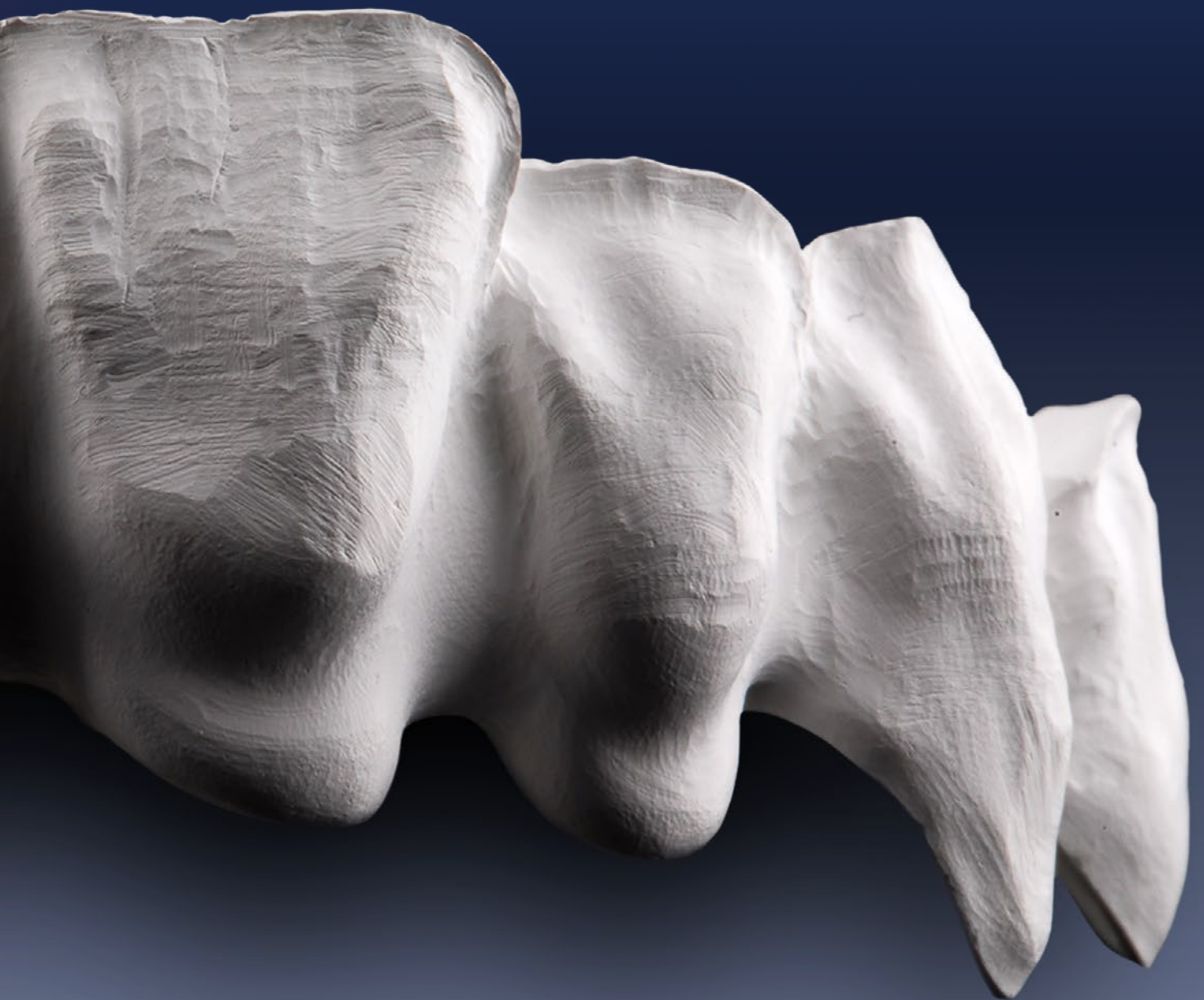


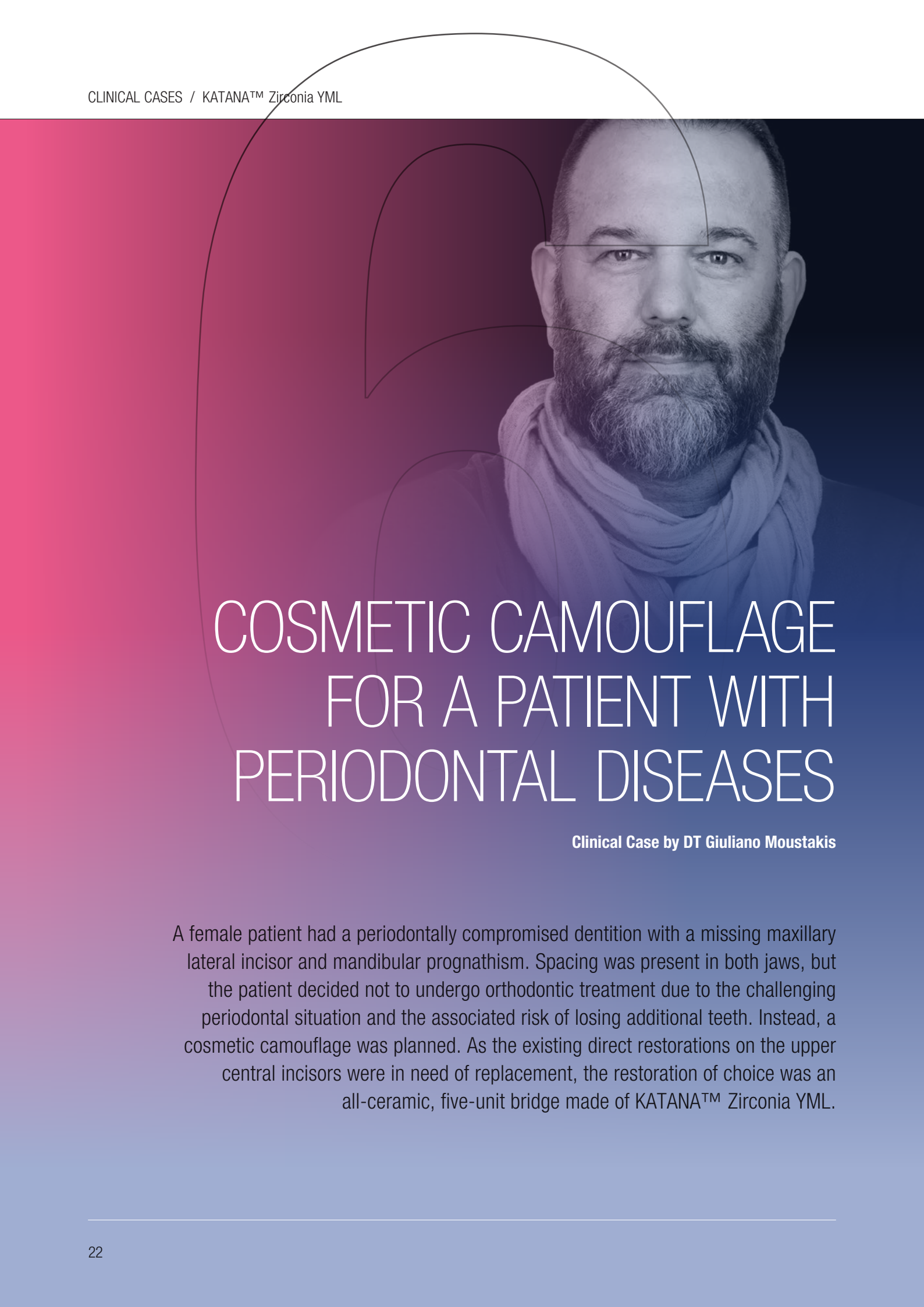
FIG. 11 Recall after 1.5 years.

CARVING: OUR TIP FOR NATURAL AESTHETICS

A natural surface texture has a similarly decisive impact on the overall aesthetics of a dental restoration as a natural play of colours. Carving of zirconia in the pre-sintered state enables you to lay the foundation for the desired natural morphology. Implementing this technique is particularly easy with KATANATM Zirconia due to its homogeneous, high-density material structure.







COSMETIC CAMOUFLAGE FOR A PATIENT WITH PERIODONTAL DISEASES

Clinical Case by DT Giuliano Moustakis

A female patient had a periodontally compromised dentition with a missing maxillary lateral incisor and mandibular prognathism. Spacing was present in both jaws, but the patient decided not to undergo orthodontic treatment due to the challenging periodontal situation and the associated risk of losing additional teeth. Instead, a cosmetic camouflage was planned. As the existing direct restorations on the upper central incisors were in need of replacement, the restoration of choice was an all-ceramic, five-unit bridge made of KATANA™ Zirconia YML.

Clinical Case 6

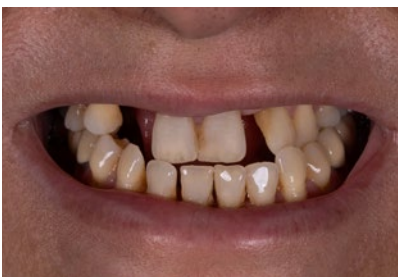

FIG. 01 Pre-operative clinical situation with a Class III malocclusion, a missing lateral incisor, spacing and periodontally compromised teeth in both jaws.

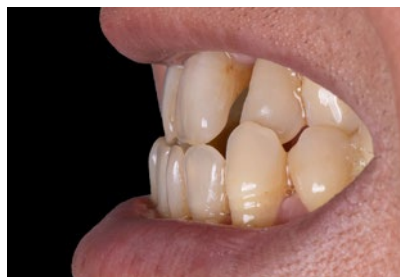

FIG. 02 Lateral view of the pre-operative situation.

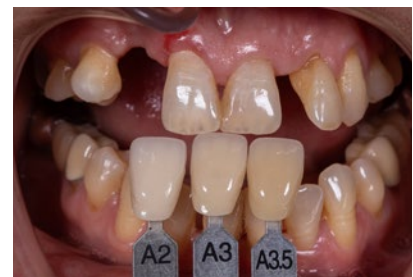

FIG. 03 Shade determination in the dental office.

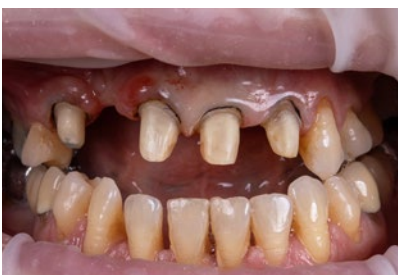

FIG. 04 Maxillary central and lateral incisors and right canine after tooth preparation.



FIG. 05 Printed models of both jaws based on an intraoral scan. This view reveals the discrepancy between the upper and lower jaws that needs to be camouflaged.

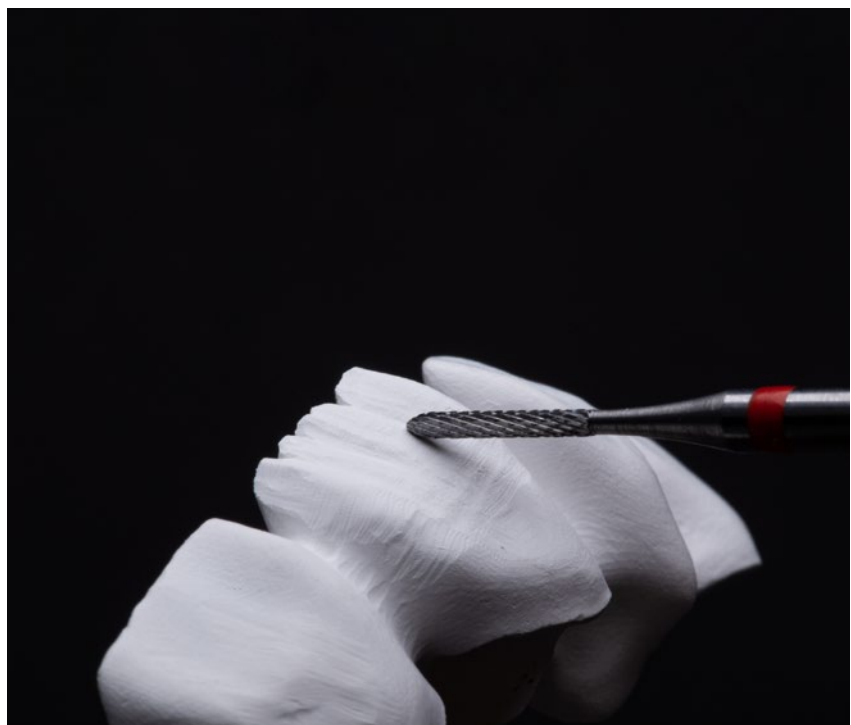

FIG. 06 Vestibular and incisal reduction and surface texturing on the pre-sintered restorations made of KATANA™ Zirconia.

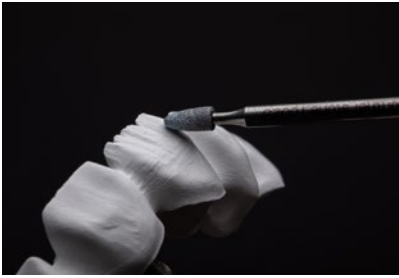

FIG. 07 Integration of horizontal growth grooves with a cone-shaped instrument (Panther Stone 040).

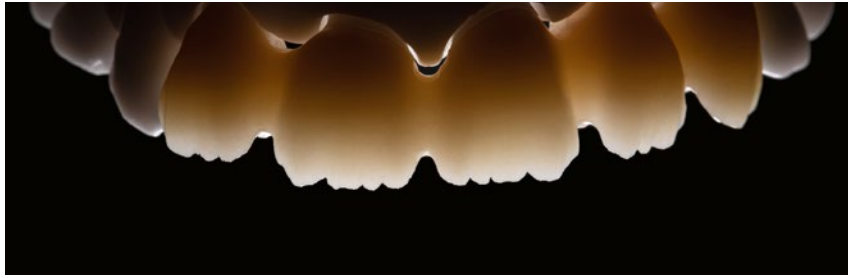


FIG. 08 Translucency of the reduced bridge after sintering.

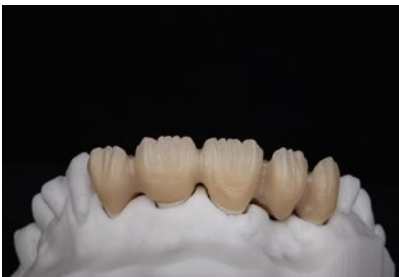

FIG. 09 KATANA™ Zirconia YML structure on the model after sintering.

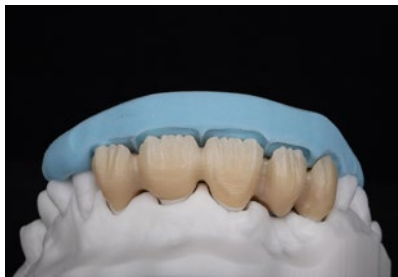

FIG. 10 Silicone index revealing the space generated in the cutback procedure.

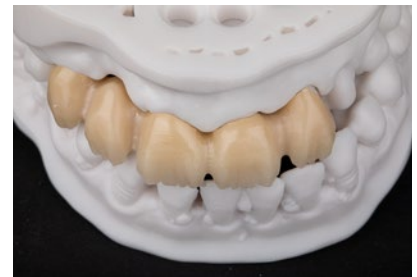

FIG. 11 Evaluation of the camouflage effect.

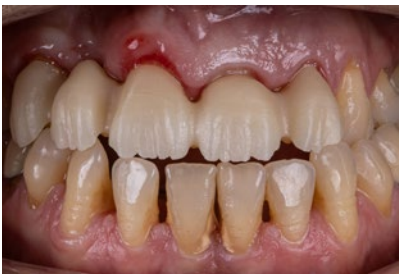

FIG. 12 Try-in of the zirconia structure.

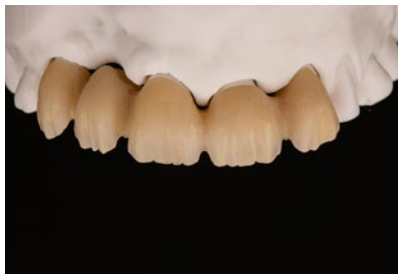

FIG. 13 Sandblasted bridge ready for microlayering.

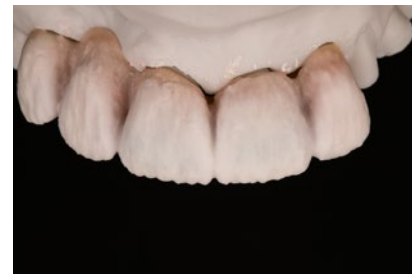

FIG. 14 After application of internal stains and a single layer of CERABIEN™ ZR Body (A3B) and Luster Porcelain (LT1, LT Royal Blue, LTx and LT Coral mixed with Incisal Aureola).

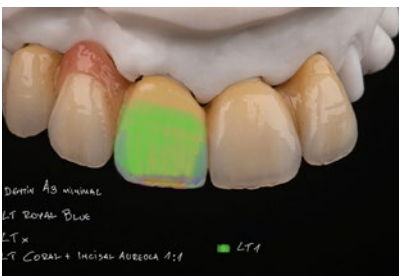

FIG. 15 Chromatic map of the micro-layering procedure.

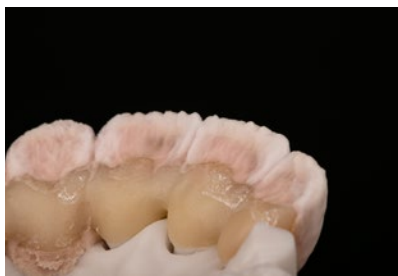

FIG. 16 Palatal view of the restoration.

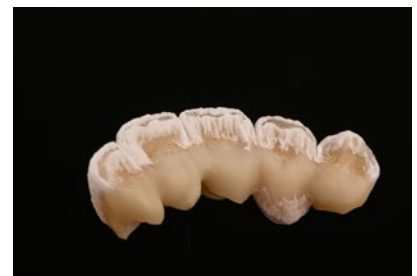

FIG. 17 Bridge after the first bake and the addition of LT1.

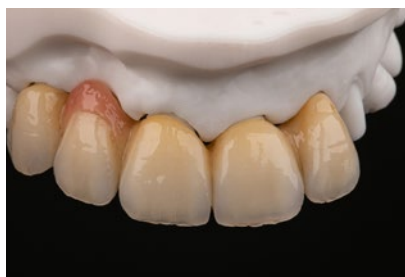

FIG. 18 Finished restoration. In order to optimize the look of tooth and gingiva parts, a final layer of CERABIEN™ ZR FC Paste Stain and Glaze was added.

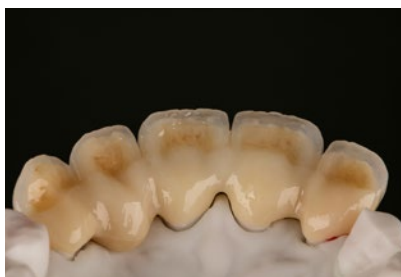

FIG. 19 Palatal view of the restoration after finishing.

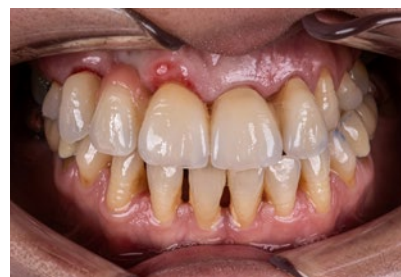

FIG. 20 Try-in of the bridge for aesthetic and functional evaluation.

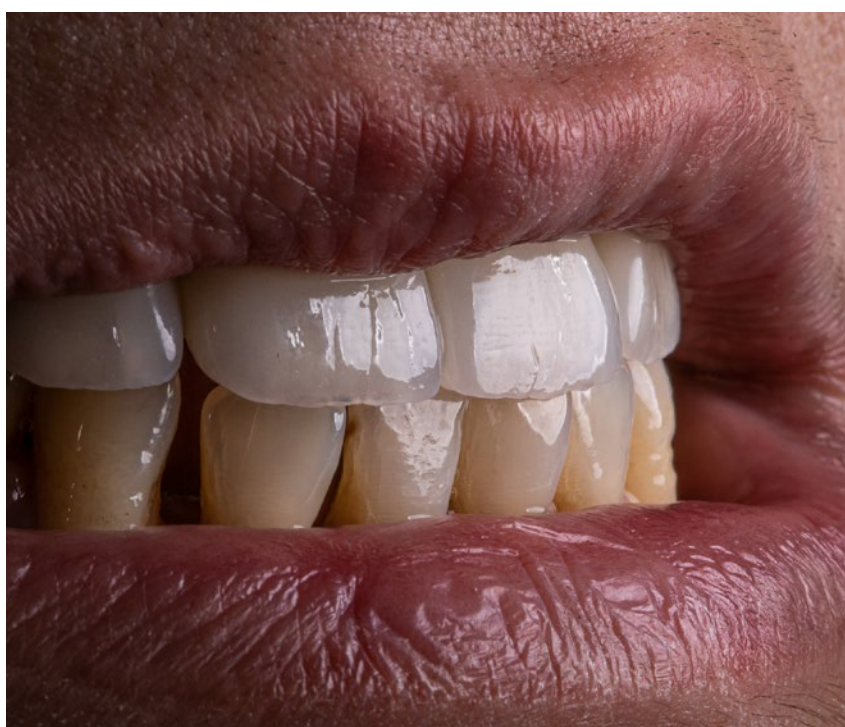

FIG. 21 Treatment outcome.



COMPLEX REHABILITATION PROCEDURE IN THE MAXILLA

**Clinical Case by Marco Valenti, DDS
and CDT Angelo Canale**

This female patient was concerned about the aesthetics of her maxillary anterior teeth. All restorations in the maxilla needed to be replaced, and the patient set great value on a long-lasting aesthetic improvement of the situation. An orthodontic correction of the malocclusion prior to restorative treatment was not an option, so that the restorations needed to be adjusted to the existing clinical situation. In order to provide for a smooth optical integration, we decided to use a single material for all restorations from the incisors up to the second premolars. This was a great chance to put the new KATANA™ Zirconia YML to a test! It was planned to use the material monolithically with zero cutback and to just paint on an ultra-thin layer of liquid ceramics (CERABIEN™ ZR FC Paste Stain).

Clinical Case 7

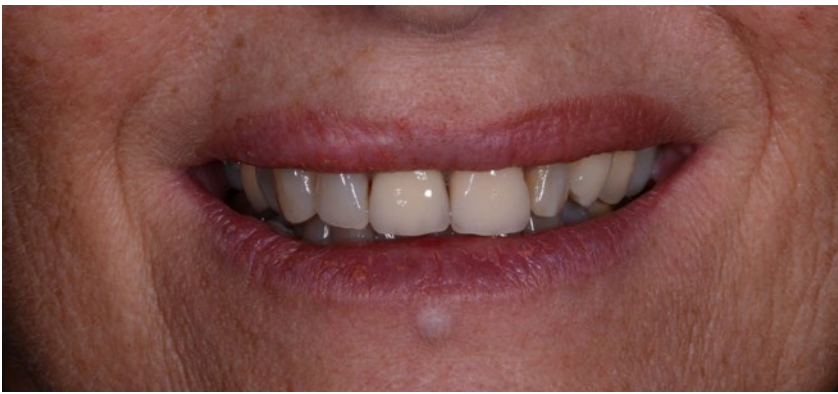

FIG. 01 Facial view of the pre-operative clinical situation.

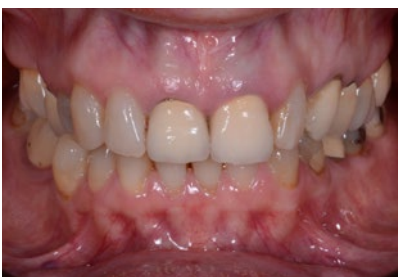

FIG. 02 Frontal intraoral view: Porcelain-fused-to-metal crowns show dark margins and an opaque core, while composite restorations affect the appearance of the natural teeth.

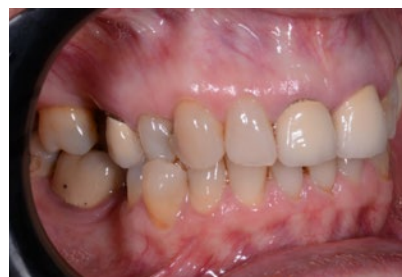

FIG. 03 Lateral view of the upper and lower right quadrant. A missing maxillary first molar has caused the second molar to drift mesially.

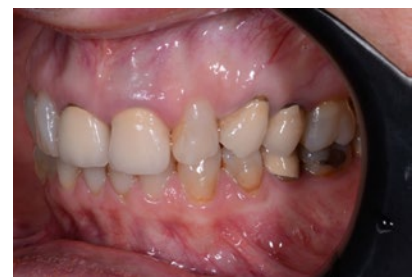

FIG. 04 Lateral view of the upper and lower left quadrant. The canine is missing, but the space has been closed.

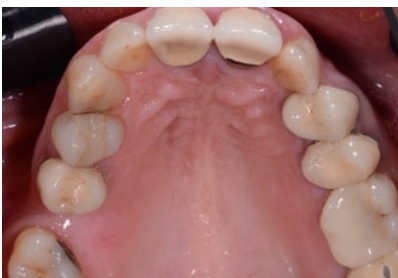

FIG. 05 Occlusal view of the maxillary teeth.

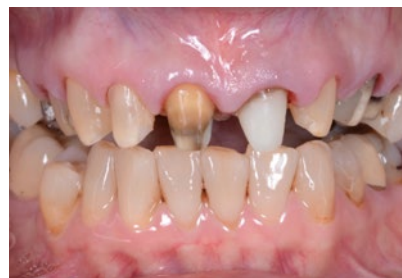

FIG. 06 Situation after tooth preparation with a heavily discoloured central incisor.

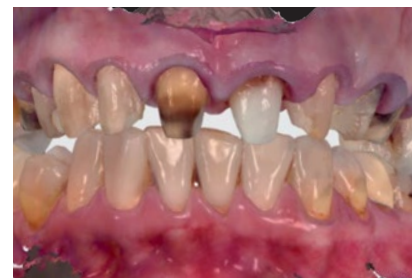

FIG. 07 Digital impression taken after tooth preparation.

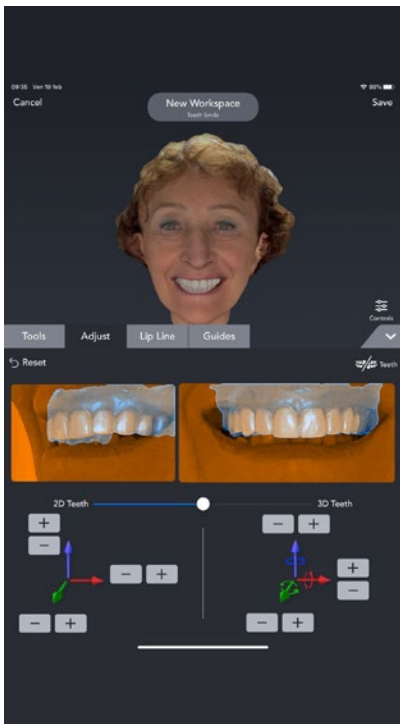


FIG. 08 Smile design for the production of the temporary.

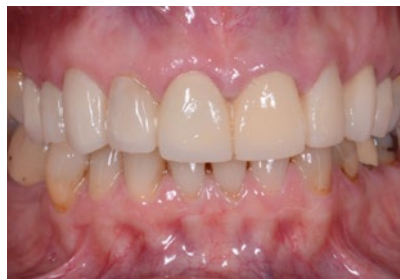

FIG. 09 Temporary restoration in place. It allowed not only for an aesthetic and functional assessment, but also for a clinical test drive of the planned definitive restorations.

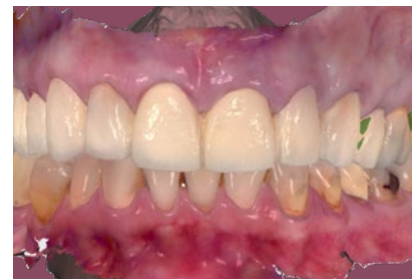

FIG. 10 Digital impression taken with the temporary restoration in place.

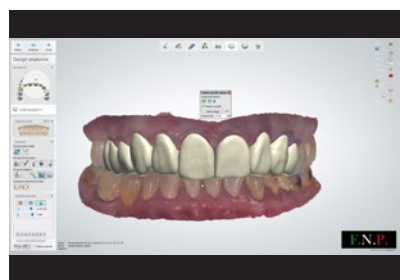


FIG. 11 Computer-aided design of four full-contour crowns, two partial crowns and one bridge.




FIG. 12 Aesthetic assessment of the virtual design.

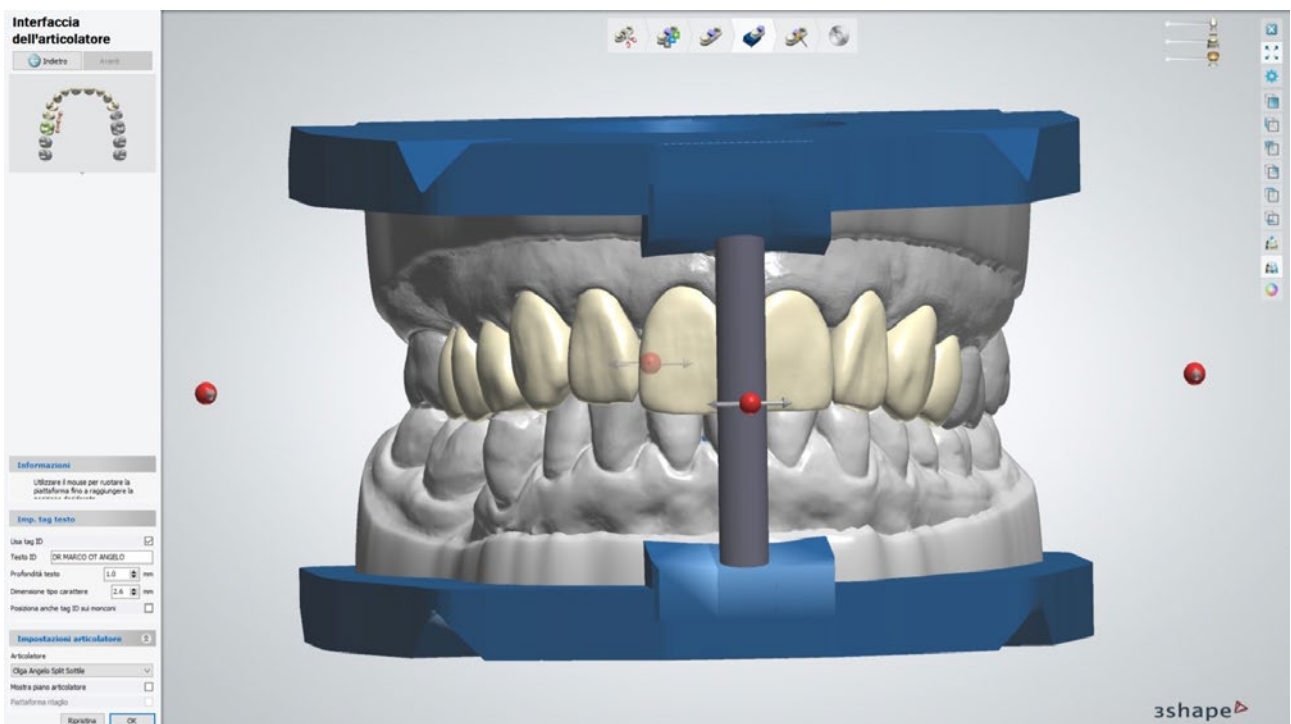


FIG. 13 Functional assessment of the virtual design.

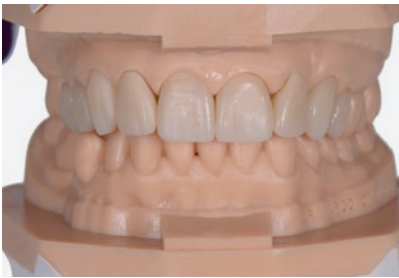

FIG. 14 Frontal view of the sintered restorations on the resin models after the addition of individual textural features with hand instruments.

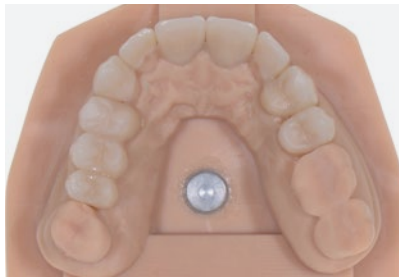

FIG. 15 Occlusal view of the restorations.

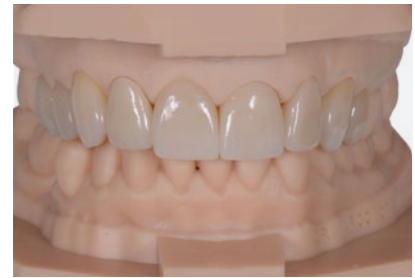

FIG. 16 Frontal view of the final restorations after adding some individual effects and glaze using the CERABIEN™ ZR FC Paste Stain kit.

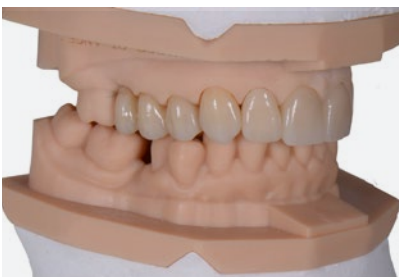

FIG. 17 Lateral view showing the bridge and the anterior crowns in the first quadrant.

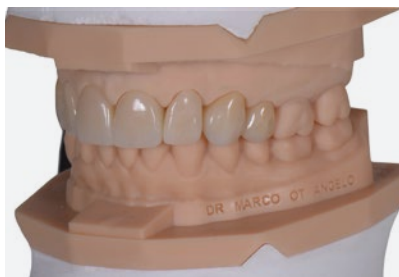

FIG. 18 Lateral view showing the crowns in the second quadrant.

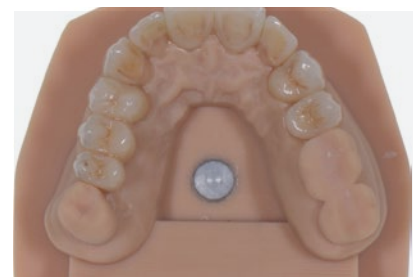

FIG. 19 Occlusal view of the lifelike restorations.

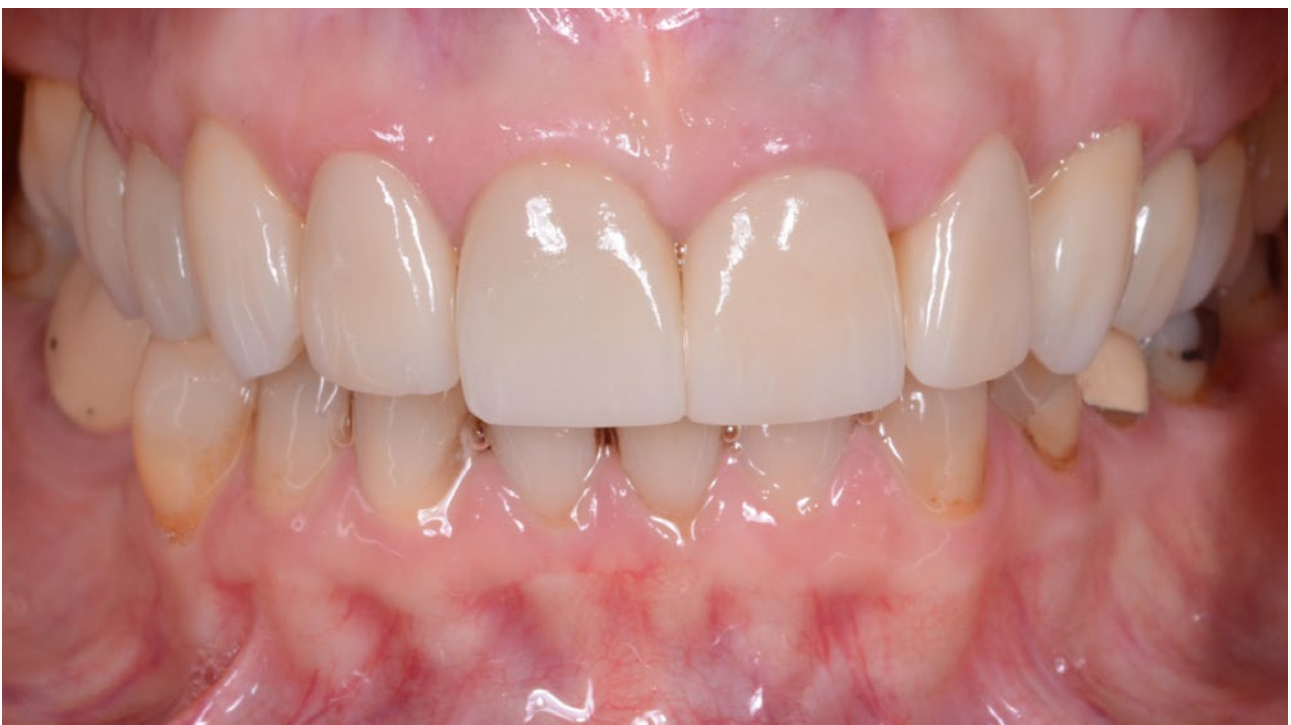

FIG. 20 Treatment outcome after definitive placement with the adhesive cementation system PANAVIA™ V5 (Kuraray Noritake Dental Inc.).



TREATMENT OF A YOUNG PATIENT WITH ZIRCONIA VENEERS

**Clinical Case by MDT Daniele Rondoni
and Dr. Enzo Attanasio**

Veneers made of zirconia? In some cases, like the one presented below, monolithic zirconia veneers may be an option. Reasons for selecting a latest-generation zirconia such as KATANA™ Zirconia YML include its very high translucency and a wall thickness of only 0.3 to 0.4 mm supporting minimally invasive tooth preparation. Due to a highly automated production procedure, the manual effort involved may be reduced, while highly aesthetic outcomes are possible.

Clinical Case 8

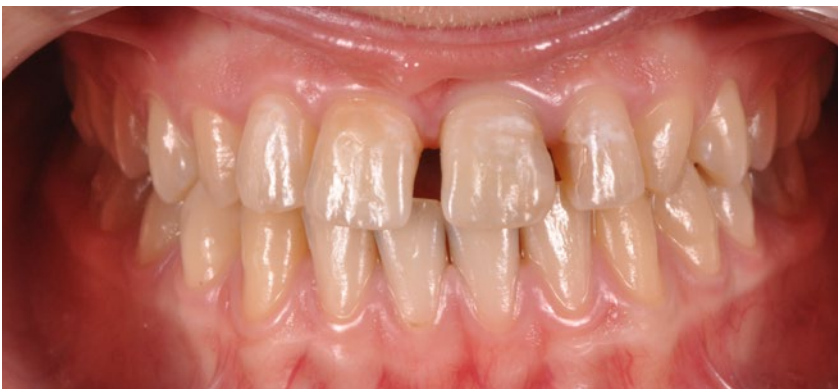

FIG. 01 Initial situation: Young female patient with misshaped and misaligned maxillary incisors.

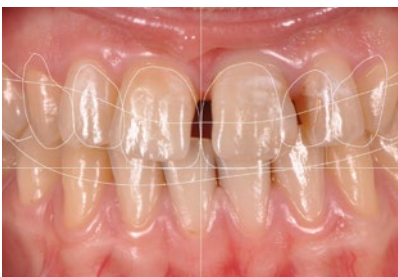

FIG. 02 Digital smile design revealing the ideal proportions and positions of the anterior teeth.

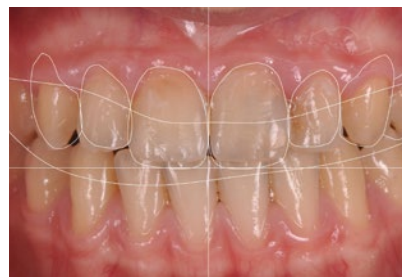

FIG. 03 Ideal tooth proportions and positions displayed over a picture of the teeth after orthodontic treatment and the creation of a mock-up.

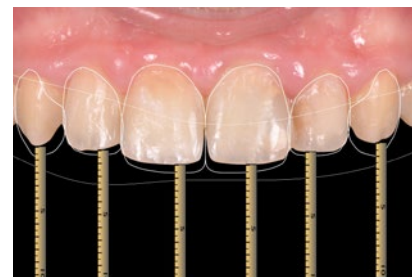

FIG. 04 Detailed view of the maxillary teeth with the ideal shapes blended in. The decision is made to produce six veneers made of KATANA™ Zirconia YML for definitive treatment.

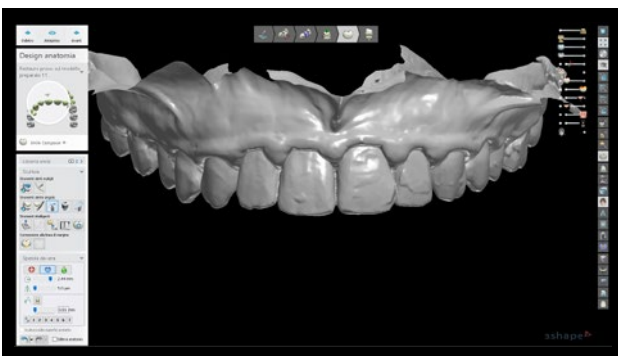

FIG. 5A Digital impression of the maxillary teeth with mock-up imported into the design software.

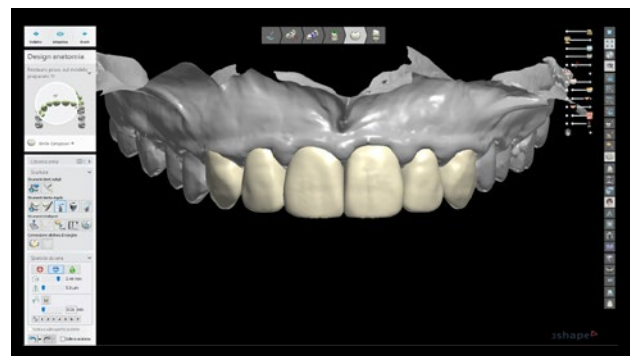

FIG. 5B Digital model of the maxilla in the CAD software with full-contour veneers designed for the incisors and canines according to the ideal shapes planned with digital smile design.

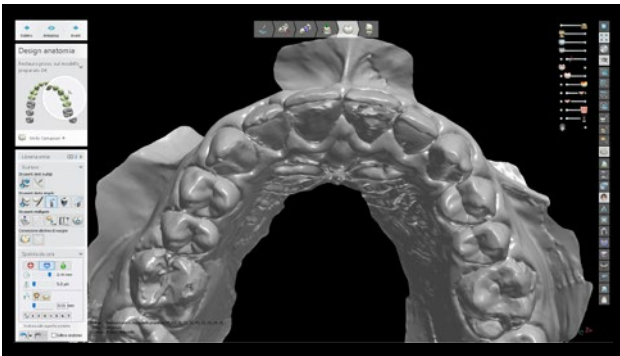


FIG. 6A Occlusal view of the virtual model.

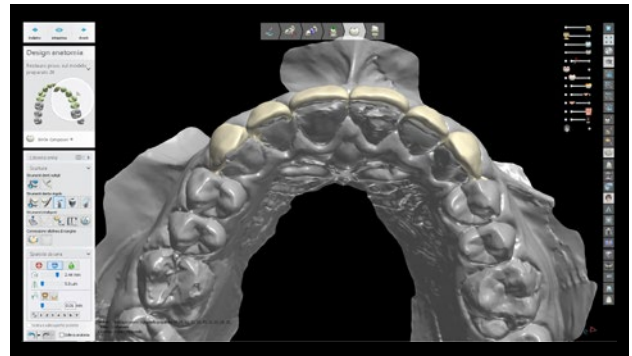


FIG. 6B Occlusal view of the model with the designed veneers.




FIG. 7A Facial view of the patient with the mock-up in place.

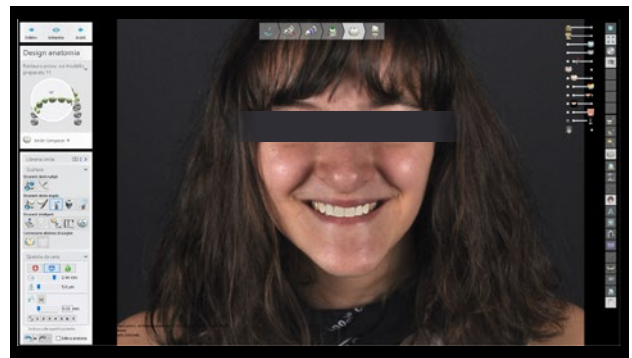


FIG. 7B Facial view of the patient with the planned veneers blended in.

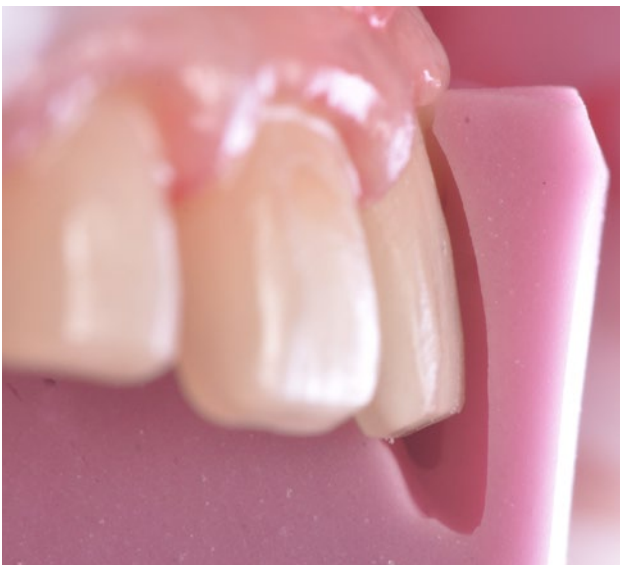

FIG. 08 Guided tooth structure removal with the aid of a silicone index.

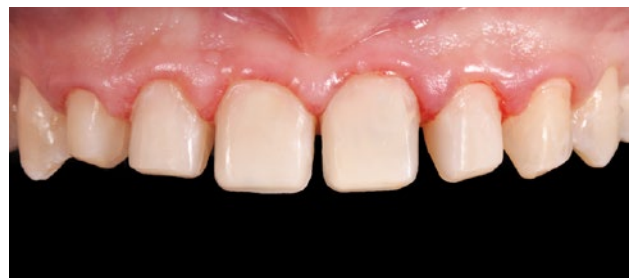

FIG. 09 Maxillary teeth immediately after minimally-invasive tooth preparation.

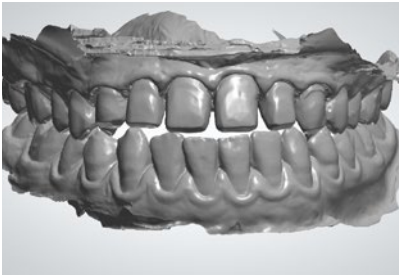


FIG. 10 Matched digital impressions of the maxilla and mandible taken after tooth preparation.

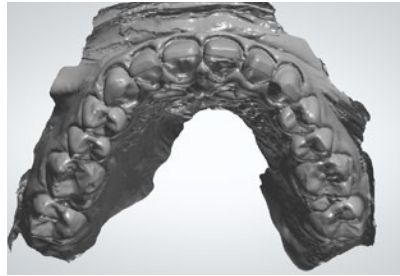


FIG. 11 Digital impression: occlusal view of the maxillary teeth.

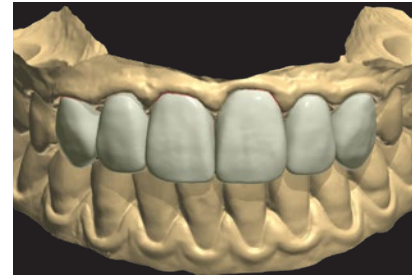

FIG. 12 Virtual veneers ready to be milled.

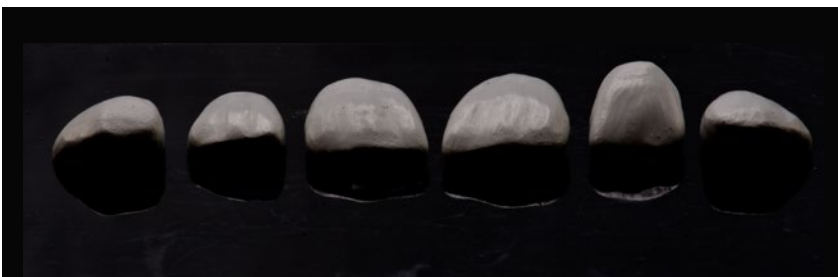

FIG. 13 Pre-sintered veneers.

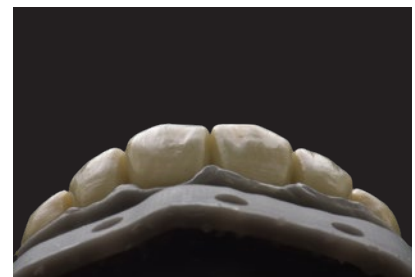

FIG. 14 Zirconia veneers on the resin model after sintering.

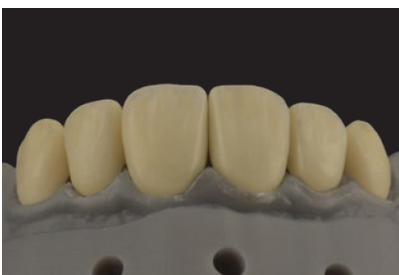

FIG. 15 Monolithic zirconia restorations on the resin model after the 7-hour final sintering.

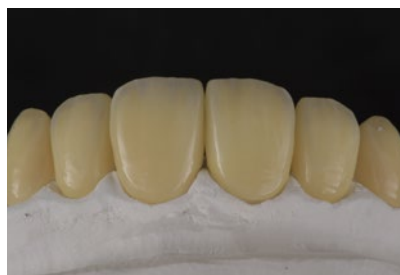

FIG. 16 Frontal view of the master cast with the six veneers individualized with the liquid ceramic system CERABIEN™ ZR FC Paste Stain.

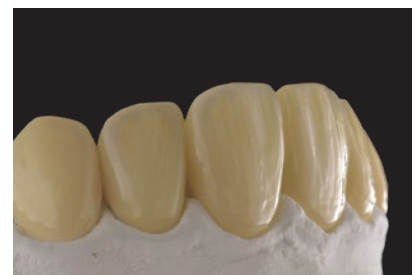

FIG. 17 Lateral view of the veneers on the master cast.

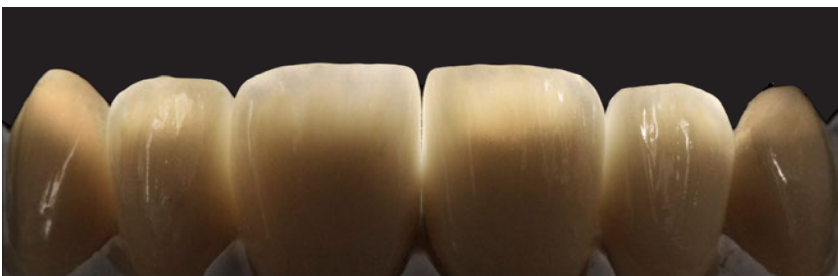


FIG. 18 Tooth-like translucency of the veneers on the model.



FIG. 19 The 0.4–0.6 mm minimal wall thickness and placement of veneers in the blank's upper enamel layer create this effect.

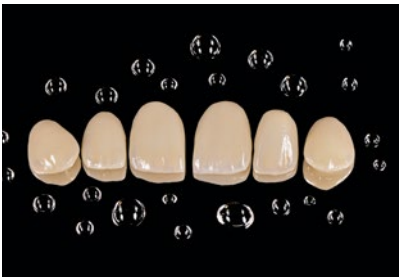

FIG. 20 Veneers ready for try-in.

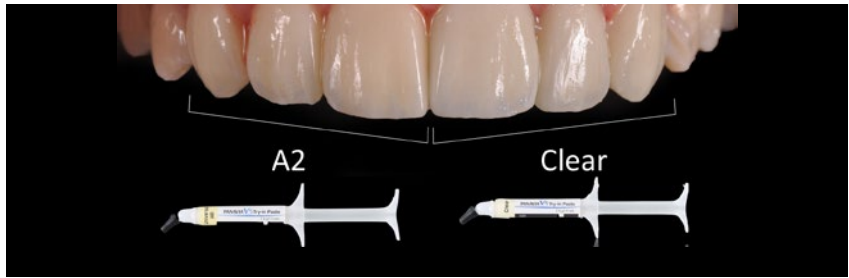


FIG. 21 Intra-oral try-in with two different shades of the PANAVIA™ V5 Try-in Paste: A2 is used in the right and Clear in the left quadrant.

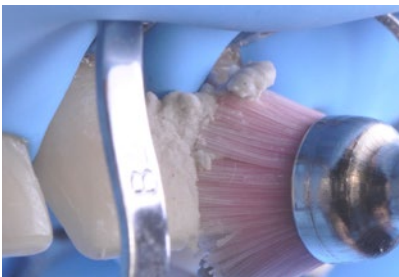


FIG. 22 Cleaning of the tooth structure with pumice paste after try-in.

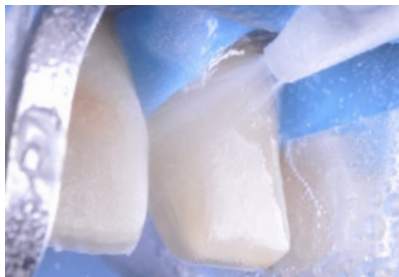

FIG. 23 Thorough rinsing with water to remove any paste residues.

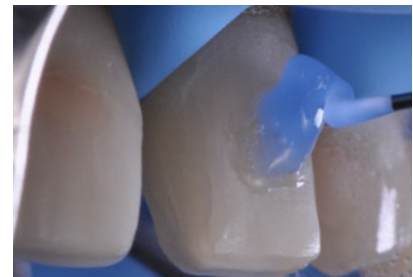

FIG. 24 Etching of the prepared tooth structure with phosphoric acid etchant.

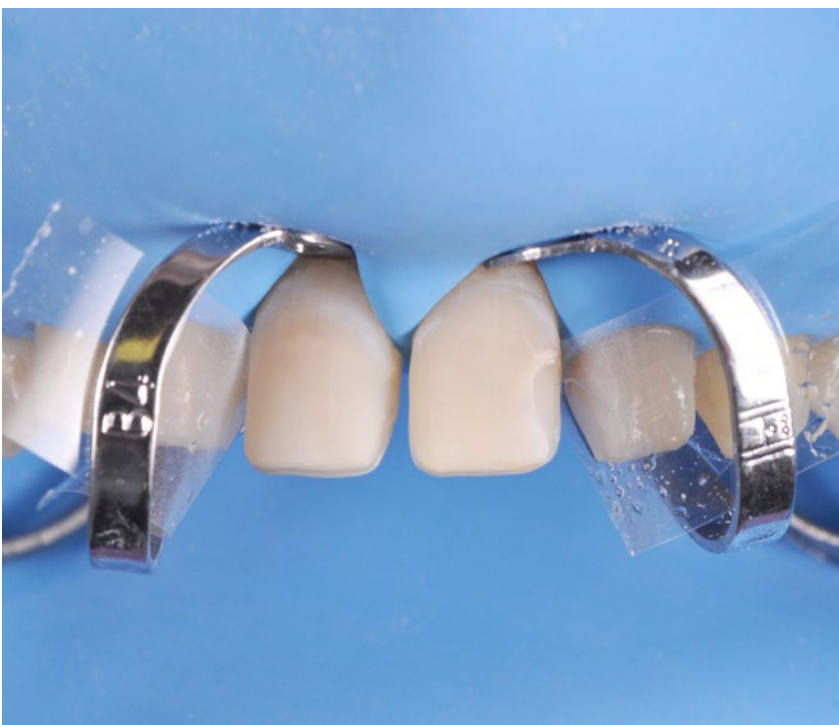

FIG. 25 Clean, isolated central incisors ready for adhesive cementation.



FIG. 26 Sandblasting of the veneer's intaglio with aluminium oxide (particle size: 50 µm, pressure: 2 bar).

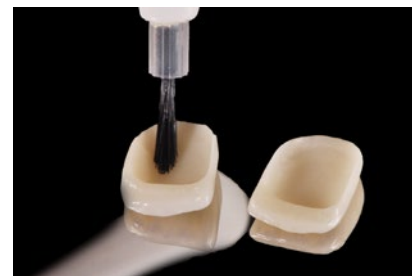

FIG. 27 Application of CLEARFIL™ CERAMIC PRIMER PLUS to the bonding surface of the veneers.

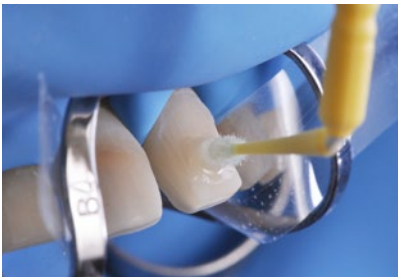

FIG. 28 Treatment of the etched tooth structure with PANA VIA™ V5 Tooth Primer (followed by mild air-drying).

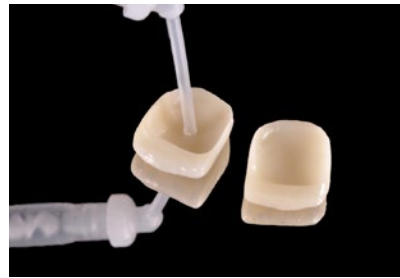

FIG. 29 Application of PANA VIA™ V5 Paste (shade A2) to the bonding surface of the veneers.

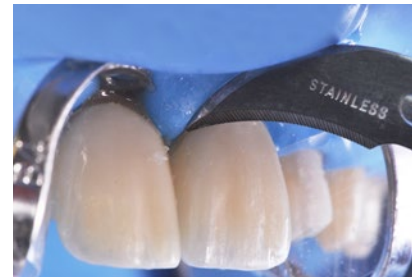

FIG. 30 Close-up view of the restoration margin during cementation. Working field isolation is a key success factor of adhesive procedures.

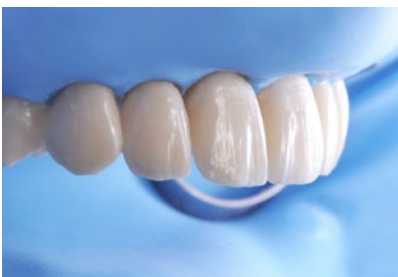

FIG. 31 Lateral view of the cemented veneers. The natural surface texture contributes to a natural appearance of the restorations.

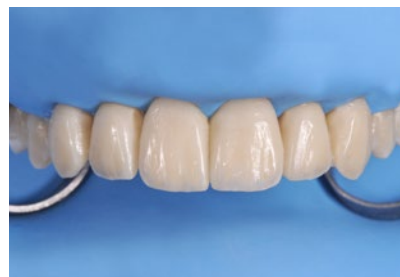

FIG. 32 Frontal view of the veneers in place.

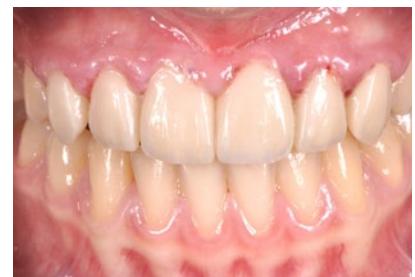

FIG. 33 Treatment outcome immediately after rubber dam removal.

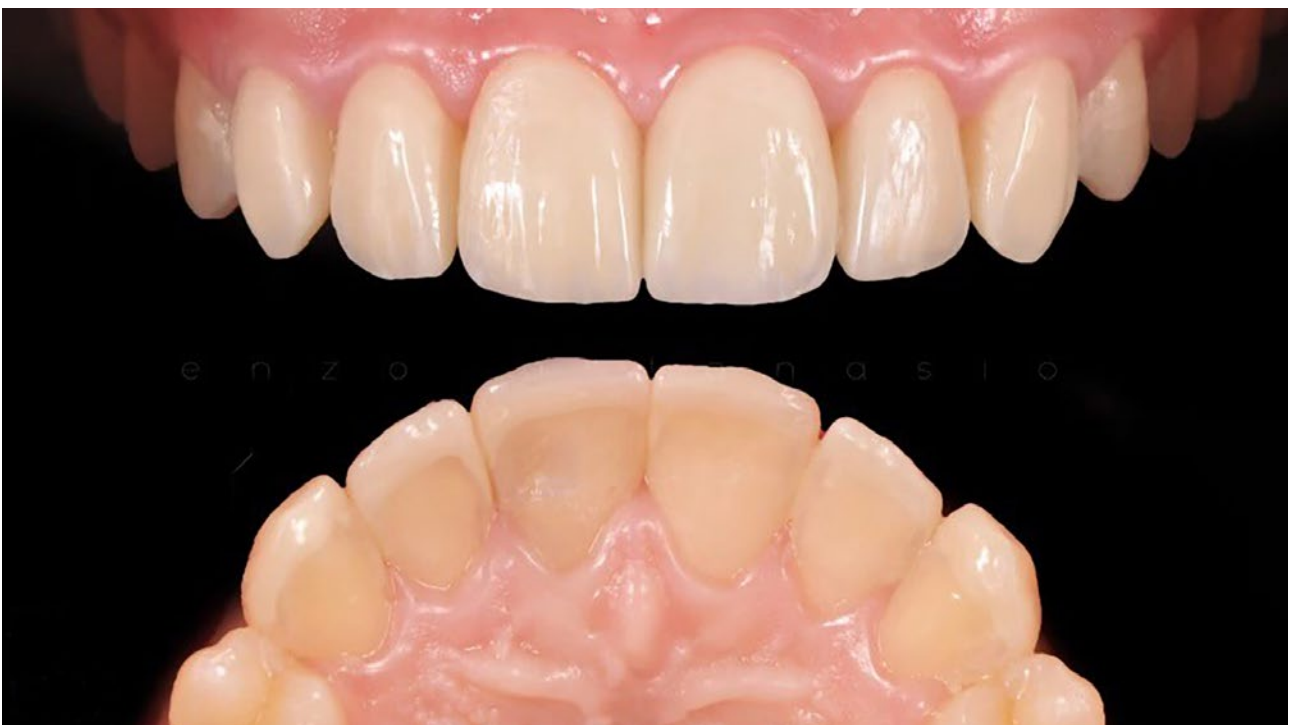

FIG. 33 Gums are healthy and the restorations show a great optical integration with the adjacent posterior teeth.



DISCOVER KATANA™ Zirconia YML



EU Importer

Kuraray Europe GmbH

Philipp-Reis-Strasse 4,
65795 Hattersheim am Main, Germany

Phone +49 (0)69 305 35 835

Fax +49 (0)69 305 98 35 835

www.kuraraynoritake.eu

centralmarketing@kuraray.com

- Before using this product, be sure to read the Instructions for Use supplied with the product.
- The specifications and appearance of the product are subject to change without notice.
- Printed color can be slightly different from actual color.

"KATANA" and "CERABIEN" are trademarks of NORITAKE CO., LIMITED.



Kuraray Noritake Dental Inc.

300 Higashiyama, Miyoshi-cho, Miyoshi, Aichi 470-0293, Japan

