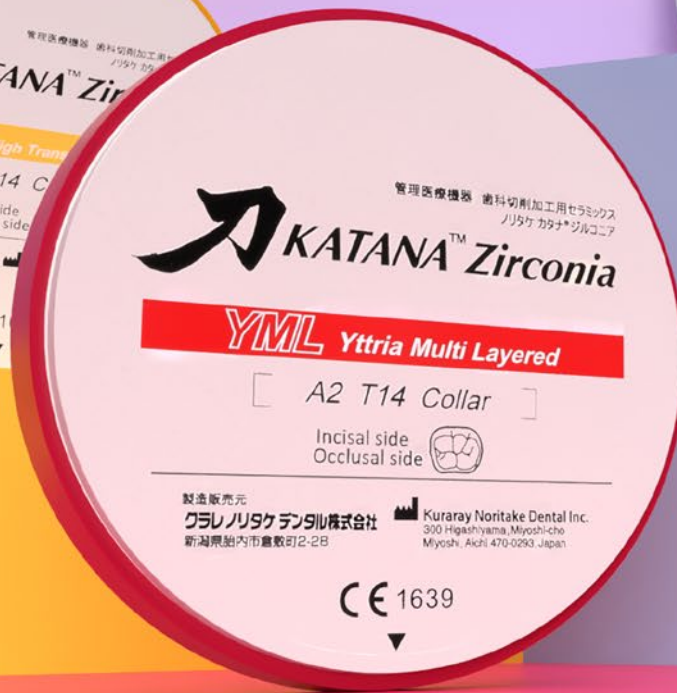

CLINICAL CASES

KATANA™ Zirconia Discs



CLINICAL CASES

KATANA™ Zirconia Discs

- 4 TREATMENT OF A YOUNG PATIENT WITH ZIRCONIA VENEERS
Clinical Case by MDT Daniele Rondoni and Dr. Enzo Attanasio
- 10 A NEW SMILE WITH ONLY 4 ZIRCONIA CROWNS
Clinical Case by DT Kanstantsin Vyshamirski
- 14 DIASTEMA CLOSURE
Clinical Case by MDT Daniele Rondoni
- 16 RESTORATION OF A SINGLE MAXILLARY INCISOR
Clinical Case by Dr. Salvatore Scolavino
- 20 ANTERIOR CROWNS ON TEETH AND IMPLANTS
Clinical Case by MDT Oriol de la Mata
- 23 EFFICIENT PRODUCTION OF A ZIRCONIA OVERDENTURE
Clinical Case by CDT Mathias Berger
- 26 MONOLITHIC POSTERIOR CROWNS AND MICRO-LAYERED ANTERIOR CROWNS
Clinical Case by MDT Shigeru Adachi
- 28 PRODUCTION OF A SCREW-RETAINED IMPLANT BRIDGE
Clinical Case by DT Pier Francesco Golfarell
- 31 FULL-MOUTH REHABILITATION USING MULTIPLE TYPES OF ZIRCONIA
Clinical Case by Dr. Davide Cortellini and CDT Angelo Canale



YML

THE STATE-OF-THE-ART ALLROUNDER

Recommended applications

- ✓ Full-arch restorations
- ✓ Long- and short-span bridges
- ✓ Anterior and posterior crowns
- ✓ Frameworks

Additional applications

- ✓ Inlays, onlays
- ✓ Veneers

Recommended finishing method

Monolithic design + ultra-micro-layering with
CERABIEN™ ZR FC Paste Stain

Alternative finishing method

Vestibular cutback (0.3 mm) + micro-layering

	Minimum wall thickness	Minimum connector cross section
Veneer	0.4 mm	-
Anterior crown	0.4 mm	-
Inlay/onlay	1.0 mm	-
Posterior crown	0.5 mm	-
Anterior 2- or 3-unit bridges	0.4 mm	7 mm ²
Anterior long-span bridge (more than 4 units)	0.4 mm	9 mm ²
Posterior bridge	0.5 mm	9 mm ²

	Translucency	Flexural Strength
Enamel	49%	750 MPa
Body 1	47%	1,000 MPa
Body 2/3	45%	1,100 Mpa

All light transmittance, illuminant: D65, Thickness of sample: 1.0 mm. White-color zirconia (base material) is used as testing material. Source: Kuraray Noritake Dental Inc.

Three point bending test according to ISO 6872:2015 - sample size 3 x 4 x 40 mm. White-color zirconia (base material) is used as testing material. Source: Kuraray Noritake Dental Inc.

Available disc thicknesses: 14 mm, 18 mm, 22 mm



TREATMENT OF A YOUNG PATIENT WITH ZIRCONIA VENEERS

**Clinical Case by MDT Daniele Rondoni
and Dr. Enzo Attanasio**

Veneers made of zirconia? In some cases, like the one presented below, monolithic zirconia veneers may be an option. Reasons for selecting a latest-generation zirconia such as KATANA™ Zirconia YML include its very high translucency and a wall thickness of only 0.3 to 0.4 mm supporting minimally invasive tooth preparation. Due to a highly automated production procedure, the manual effort involved may be reduced, while highly aesthetic outcomes are possible.

Clinical Case 1

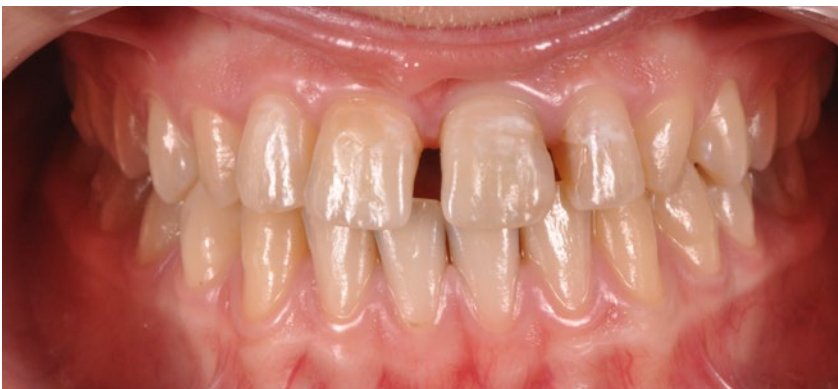

FIG. 01 Initial situation: Young female patient with misshaped and misaligned maxillary incisors.

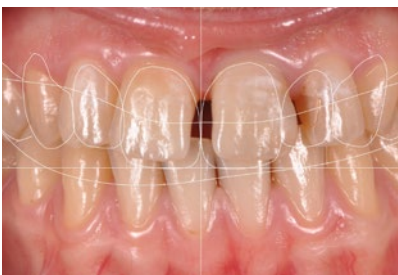

FIG. 02 Digital smile design revealing the ideal proportions and positions of the anterior teeth.

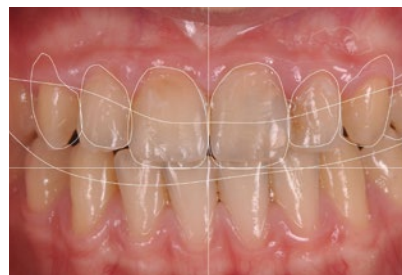

FIG. 03 Ideal tooth proportions and positions displayed over a picture of the teeth after orthodontic treatment and the creation of a mock-up.

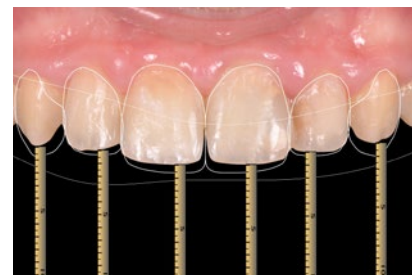


FIG. 04 Detailed view of the maxillary teeth with the ideal shapes blended in. The decision is made to produce six veneers made of KATANA™ Zirconia YML for definitive treatment.

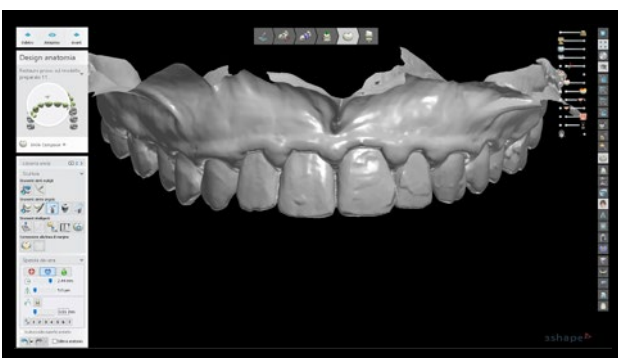

FIG. 5A Digital impression of the maxillary teeth with mock-up imported into the design software.

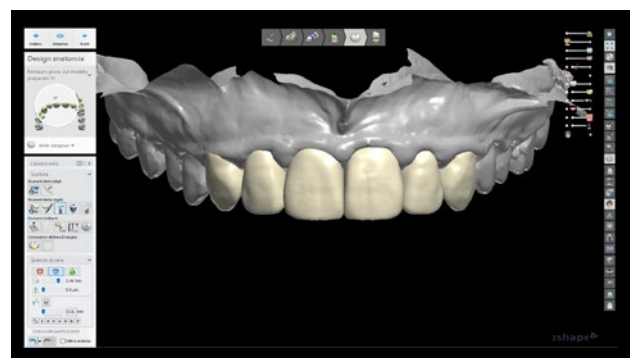


FIG. 5B Digital model of the maxilla in the CAD software with full-contour veneers designed for the incisors and canines according to the ideal shapes planned with digital smile design.

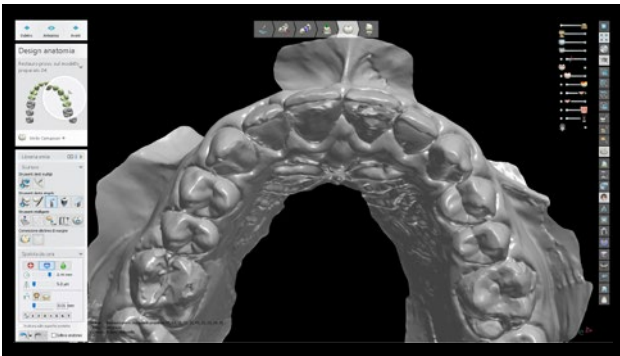


FIG. 6A Occlusal view of the virtual model.

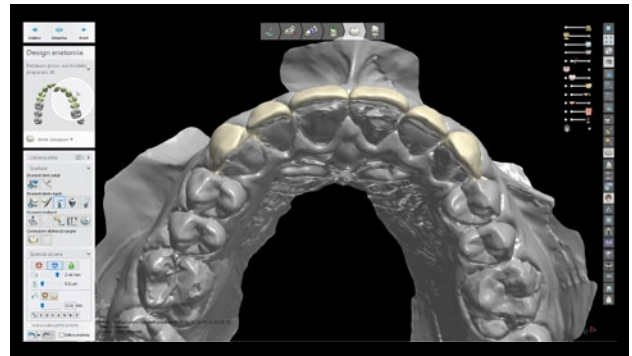


FIG. 6B Occlusal view of the model with the designed veneers.




FIG. 7A Facial view of the patient with the mock-up in place.

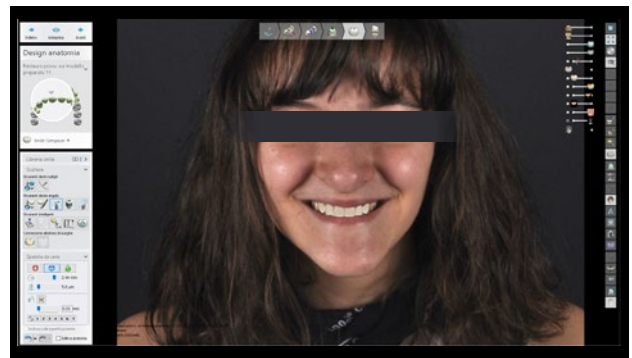


FIG. 7B Facial view of the patient with the planned veneers blended in.

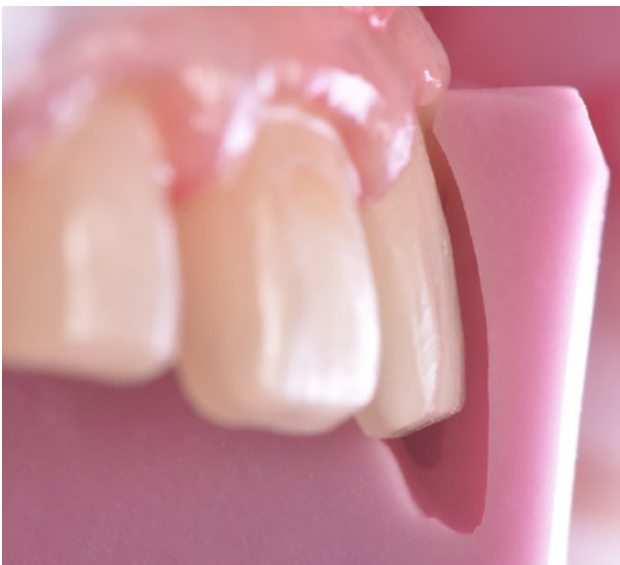

FIG. 08 Guided tooth structure removal with the aid of a silicone index.

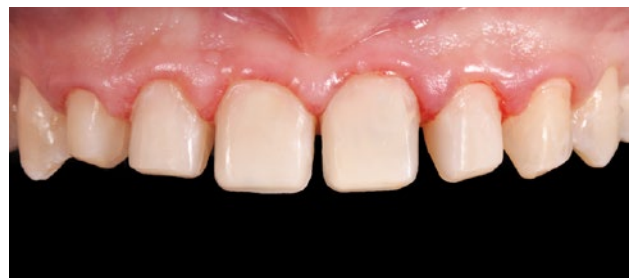

FIG. 09 Maxillary teeth immediately after minimally-invasive tooth preparation.

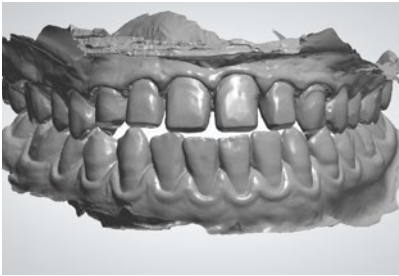


FIG. 10 Matched digital impressions of the maxilla and mandible taken after tooth preparation.

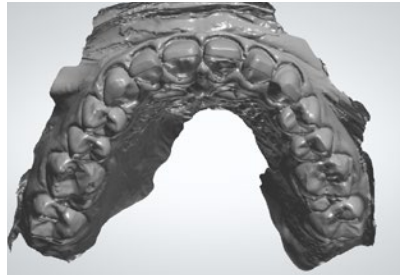


FIG. 11 Digital impression: occlusal view of the maxillary teeth.

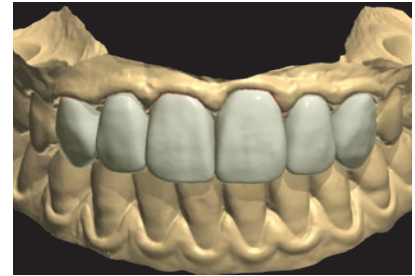

FIG. 12 Virtual veneers ready to be milled.

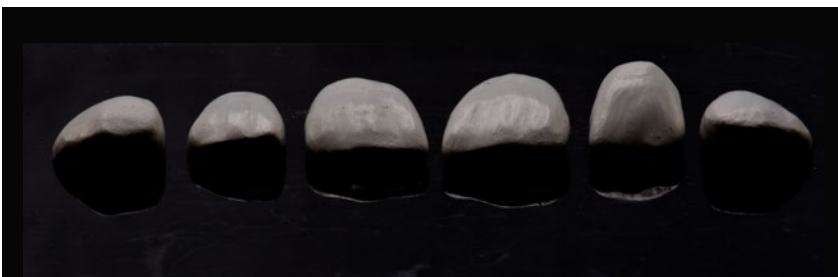

FIG. 13 Pre-sintered veneers.

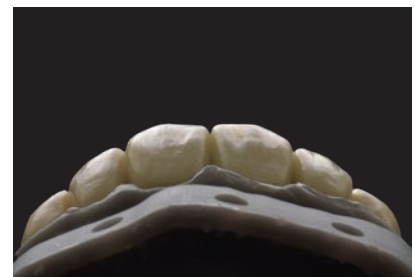

FIG. 14 Zirconia veneers on the resin model after sintering.

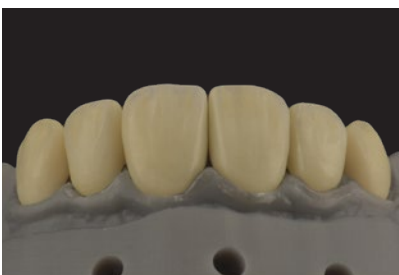

FIG. 15 Monolithic zirconia restorations on the resin model after the 7-hour final sintering.

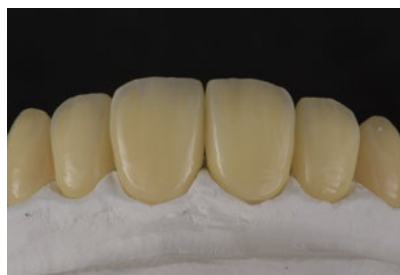

FIG. 16 Frontal view of the master cast with the six veneers individualized with the liquid ceramic system CERABIEN™ ZR FC Paste Stain.

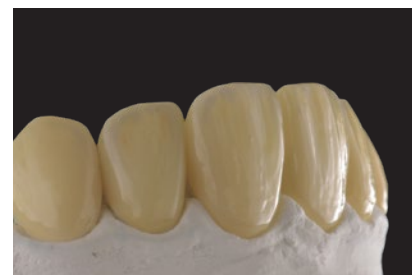

FIG. 17 Lateral view of the veneers on the master cast.

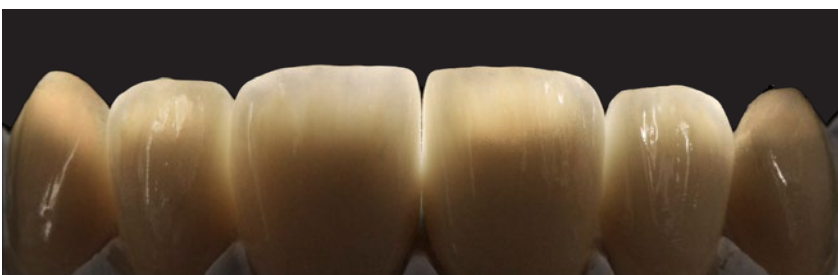


FIG. 18 Tooth-like translucency of the veneers on the model.



FIG. 19 The 0.4–0.6 mm minimal wall thickness and placement of veneers in the blank's upper enamel layer create this effect.

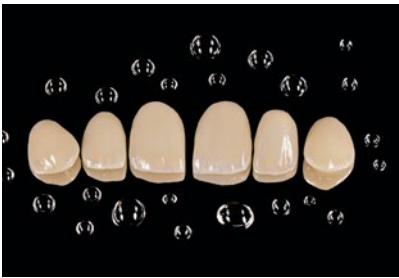

FIG. 20 Veneers ready for try-in.

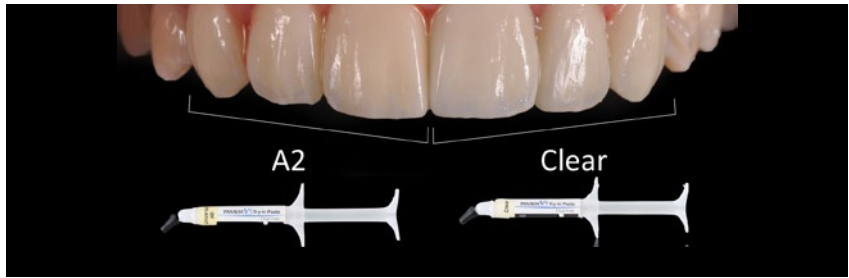


FIG. 21 Intra-oral try-in with two different shades of the PANAVIA™ V5 Try-in Paste: A2 is used in the right and Clear in the left quadrant.

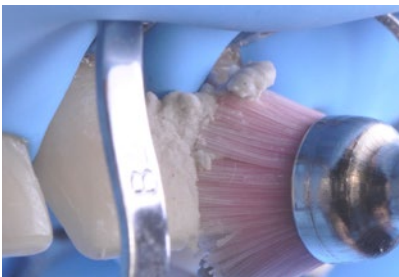


FIG. 22 Cleaning of the tooth structure with pumice paste after try-in.

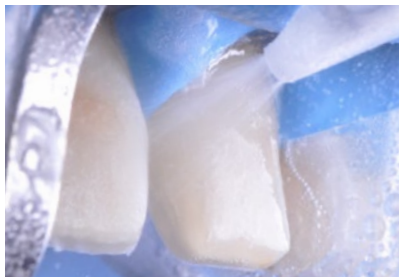

FIG. 23 Thorough rinsing with water to remove any paste residues.

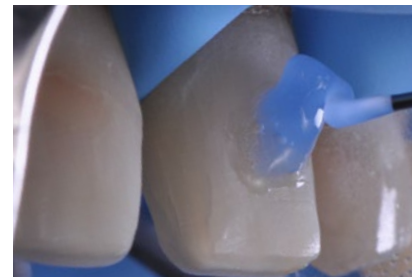

FIG. 24 Etching of the prepared tooth structure with phosphoric acid etchant.

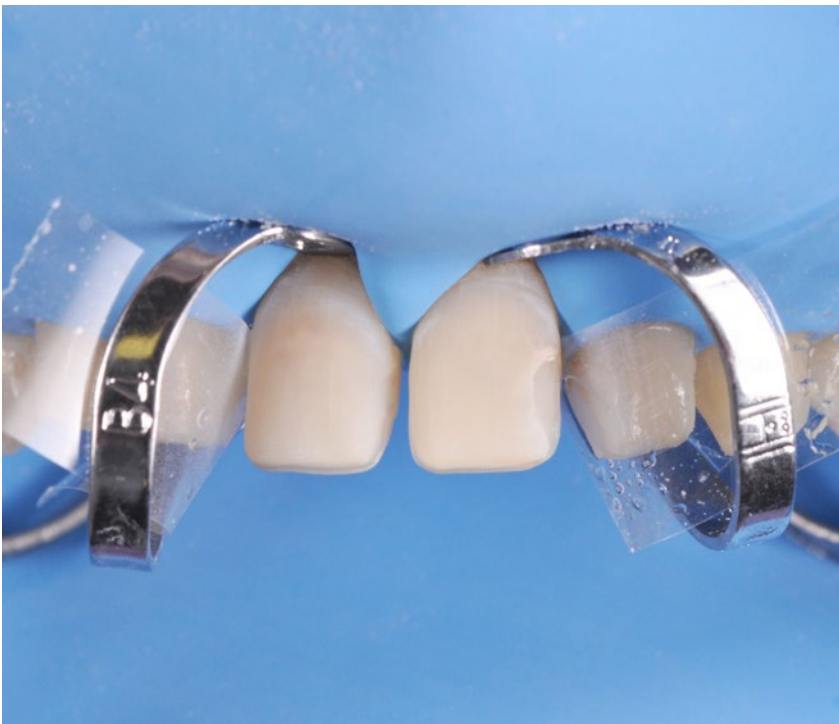

FIG. 25 Clean, isolated central incisors ready for adhesive cementation.



FIG. 26 Sandblasting of the veneer's intaglio with aluminium oxide (particle size: 50 µm, pressure: 2 bar).

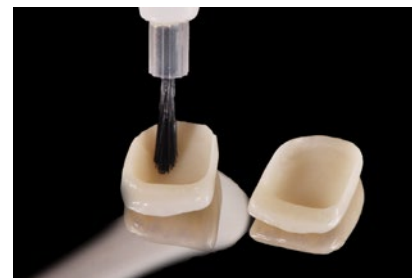

FIG. 27 Application of CLEARFIL™ CERAMIC PRIMER PLUS to the bonding surface of the veneers.

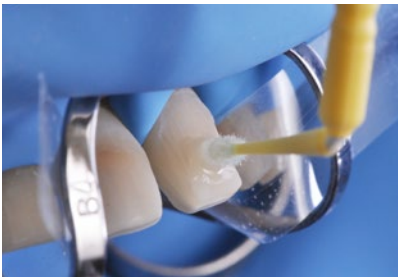

FIG. 28 Treatment of the etched tooth structure with PANAIA™ V5 Tooth Primer (followed by mild air-drying).

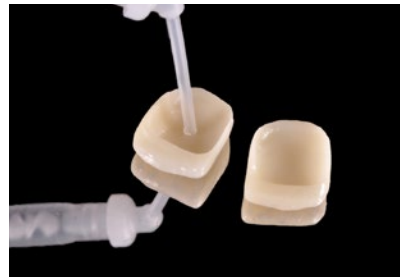

FIG. 29 Application of PANAIA™ V5 Paste (shade A2) to the bonding surface of the veneers.

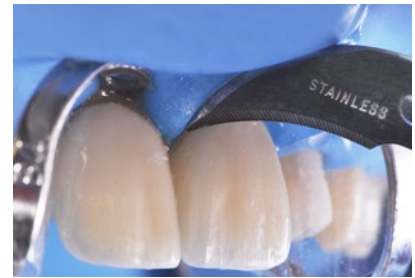

FIG. 30 Close-up view of the restoration margin during cementation. Working field isolation is a key success factor of adhesive procedures.

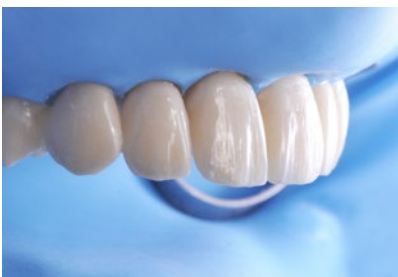

FIG. 31 Lateral view of the cemented veneers. The natural surface texture contributes to a natural appearance of the restorations.

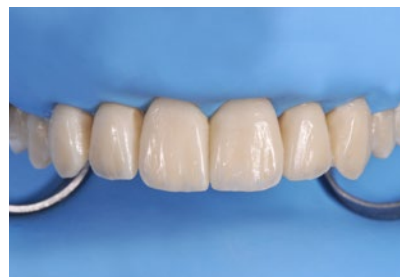

FIG. 32 Frontal view of the veneers in place.

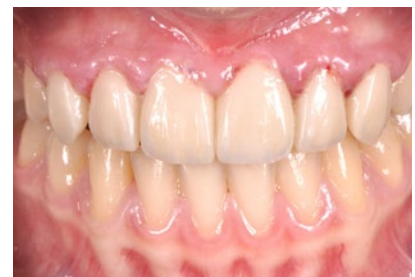

FIG. 33 Treatment outcome immediately after rubber dam removal.

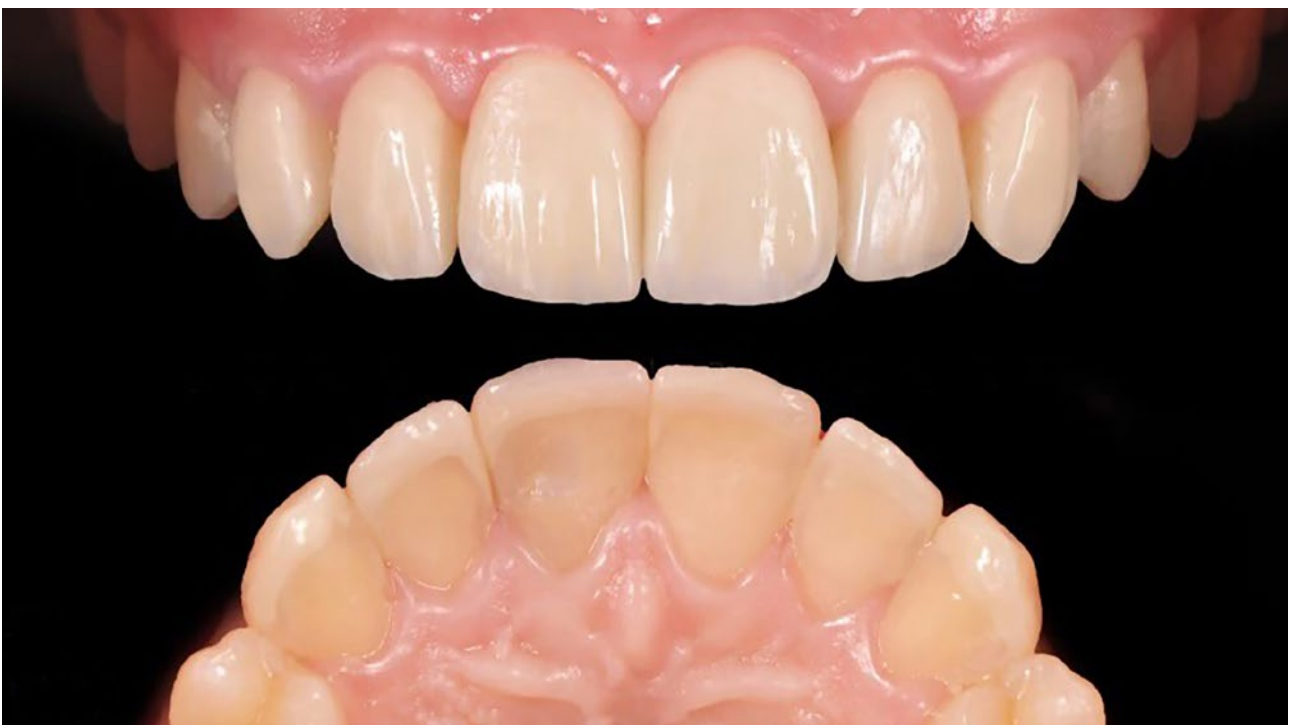

FIG. 33 Gums are healthy and the restorations show a great optical integration with the adjacent posterior teeth.



A NEW SMILE WITH ONLY 4 ZIRCONIA CROWNS

Clinical Case by DT Kanstantsin Vyshamirski

A male patient (47 years of age) presented to his dentist with severe damage to his teeth. His main request was to increase aesthetics, to achieve a more pleasing envisaged aesthetic area. A side request was to achieve a 'whitening but natural look'. This was achieved by using a lighter colour palette of zirconia and porcelain materials. The final result was achieved through the creation of a wax-up, followed by a mock-up, provisional restoration and finally adhesive bonding of the zirconia crowns.

Clinical Case 2

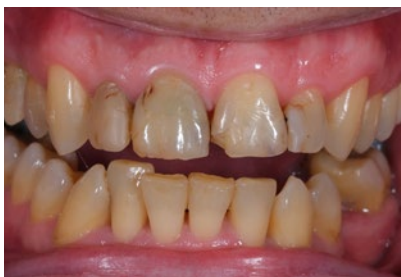

FIG. 01 Initial situation. Male patient (age 47).

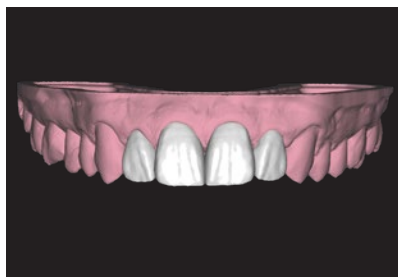

FIG. 02 Planning the new smile according to the patient's aesthetic and functional parameters.

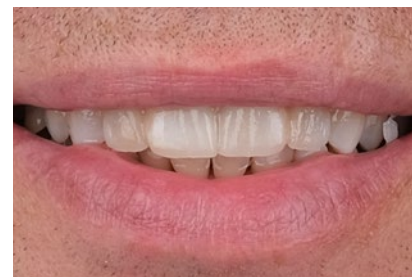

FIG. 03 Mock-up in place to check the new look in the patient's mouth.

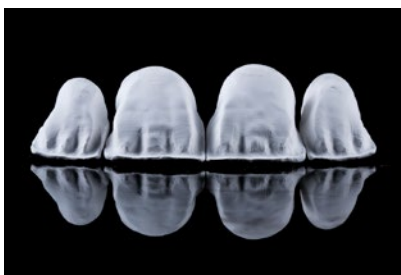

FIG. 04 KATANA™ Zirconia YML shade A1 crowns with labial cutback after milling.

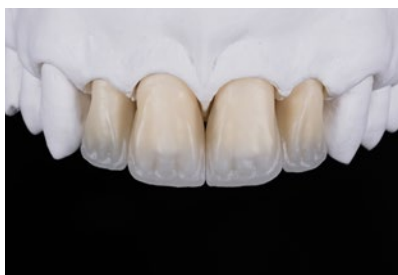


FIG. 05 Crowns after sintering on the plaster model.

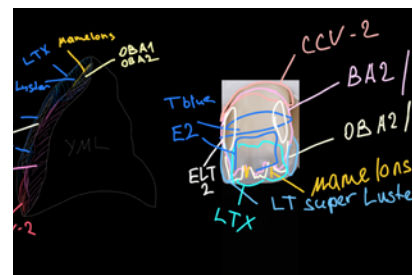


FIG. 06 Noritake CERABIEN™ ZR porcelain layering map.

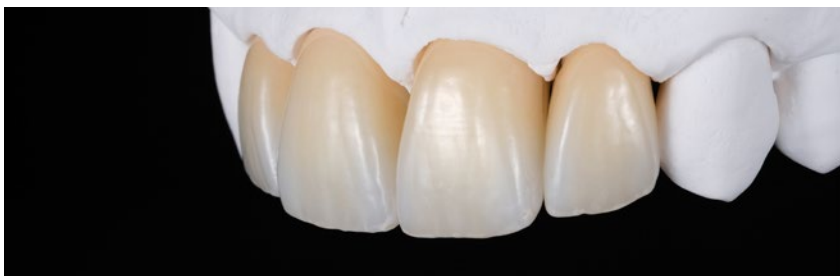

FIG. 07 Finishing the labial surface using both polishing and selfglaze. On the palatal side of the crowns, only CERABIEN™ FC Paste Stain stains and glaze were used for finishing. To aid in optimisation of the soft tissue condition, the palato-cervical and near proximal areas were polished.

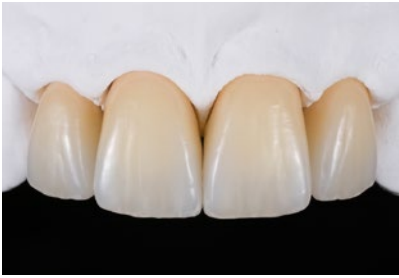

FIG. 08 Finished crowns on the plaster model.

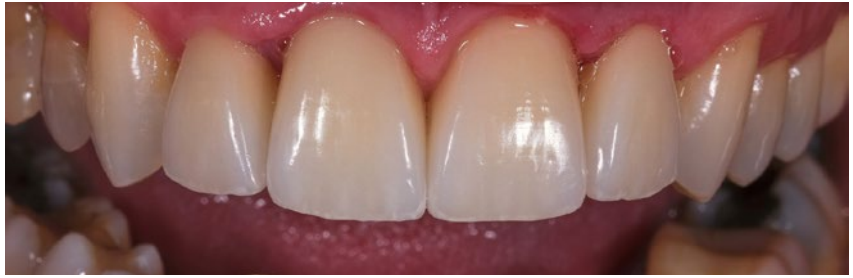

FIG. 09 Try-in using PANA VIA™ V5 White try-in paste, to confirm the proper appearance. For the final adhesive cementation, PANA VIA™ V5 White has been used.

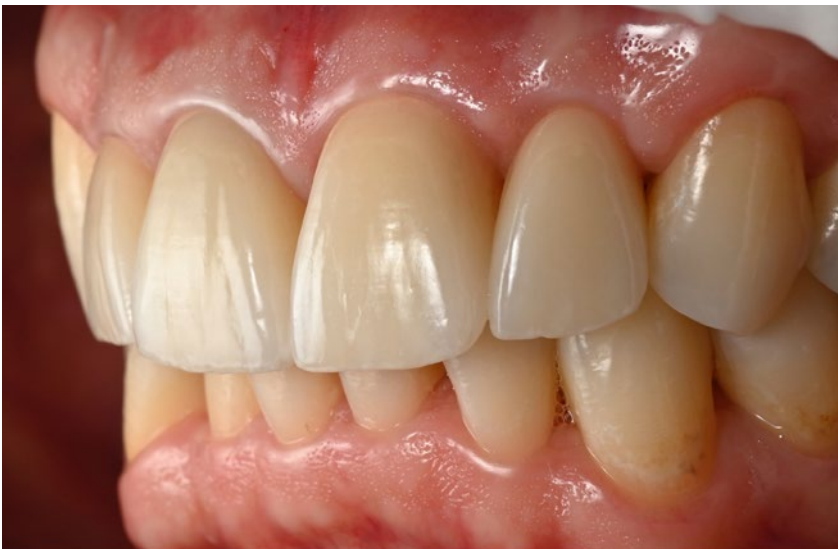

FIG. 10 Situation after seven months. The result is aesthetically pleasing and the gingival condition excellent.

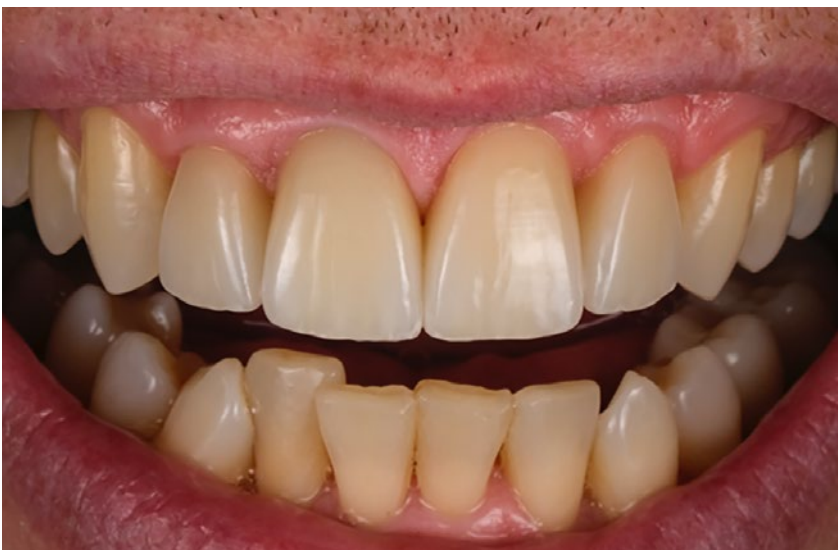

FIG. 11 Recall after 1.5 years.



STML

THE FIRST CHOICE
FOR CROWNS AND UP
TO 3-UNIT BRIDGES

Recommended applications

- ✓ Anterior crowns and up to 3-unit bridges
- ✓ Posterior crowns and up to 3-unit bridges

Additional applications

- ✓ Inlays, onlays
- ✓ Veneers

Recommended finishing method

Monolithic design + ultra-micro-layering with CERABIEN™ ZR FC Paste Stain

Alternative finishing method

Vestibular cutback (0.3 mm) + micro-layering

	Minimum wall thickness	Minimum connector cross section
Veneer	0.4 mm	-
Anterior crown	0.8 mm	-
Inlay/onlay	1.0 mm	-
Posterior crown	1.0 mm	-
Anterior 2- or 3-unit bridges	0.8 mm	12 mm ²
Posterior 2- or 3-unit bridges	1.0 mm	16 mm ²

Translucency

49%

Flexural Strength

748 MPa

All light transmittance, illuminant: D65, Thickness of sample: 1.0 mm. White-color zirconia (base material) is used as testing material. Source: Kuraray Noritake Dental Inc.

Three point bending test according to ISO 6872:2015 - sample size 3 x 4 x 40 mm. Source: Kuraray Noritake Dental Inc.

Available disc thicknesses: 14 mm, 18 mm, 22 mm



DIASTEMA CLOSURE

With **KATANA™ STML** and **CZR FC Paste Stain**

Clinical Case by **MDT Daniele Rondoni**

A middle-aged patient sought dental advice because she felt uncomfortable with the aesthetic appearance of her maxillary incisors. Additionally, she was not happy about the diastema between her upper central incisors. Tooth 21 (FDI notation) had undergone an endodontic treatment, while teeth 11 to 22 had been newly built up. Due to the deteriorated conditions, all affected teeth were taken into consideration in the planning and designing of new restorations, including the intention to close the diastema. The best suitable material for a natural look in combination with a close gingival attachment to the restoration is, in this case, zirconia, because of its biocompatibility and gentleness to the gingival region.

Clinical Case 3

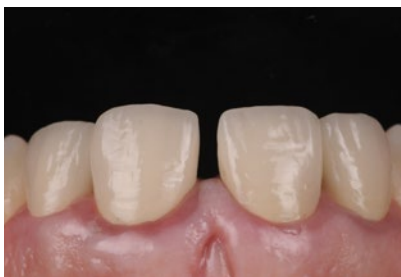

FIG. 01 Initial situation.

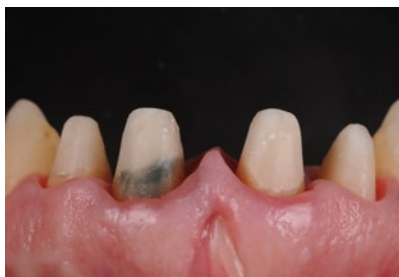

FIG. 02 Preparations, showing discoloration in the cervical area of tooth 21.

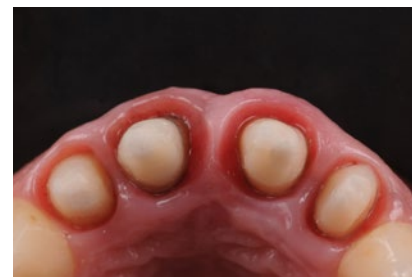

FIG. 03 Occlusal view of the preparations.

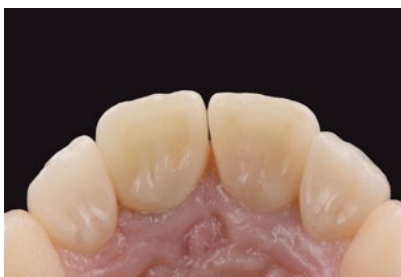

FIG. 04 The four zirconia crowns after designing followed by milling.

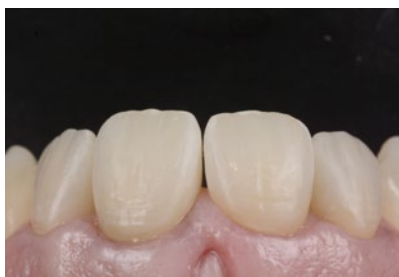

FIG. 05 Result directly after sintering.

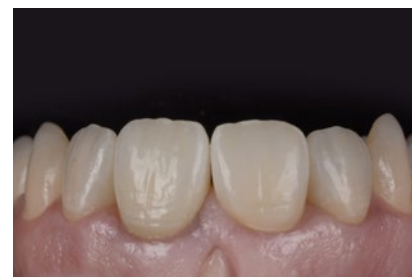

FIG. 06 Characterization of the restoration with CERABIEN™ ZR FC Paste Stain.

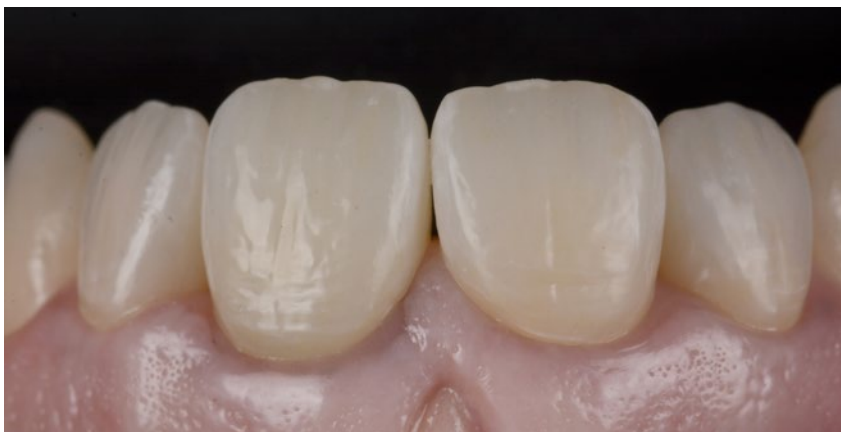
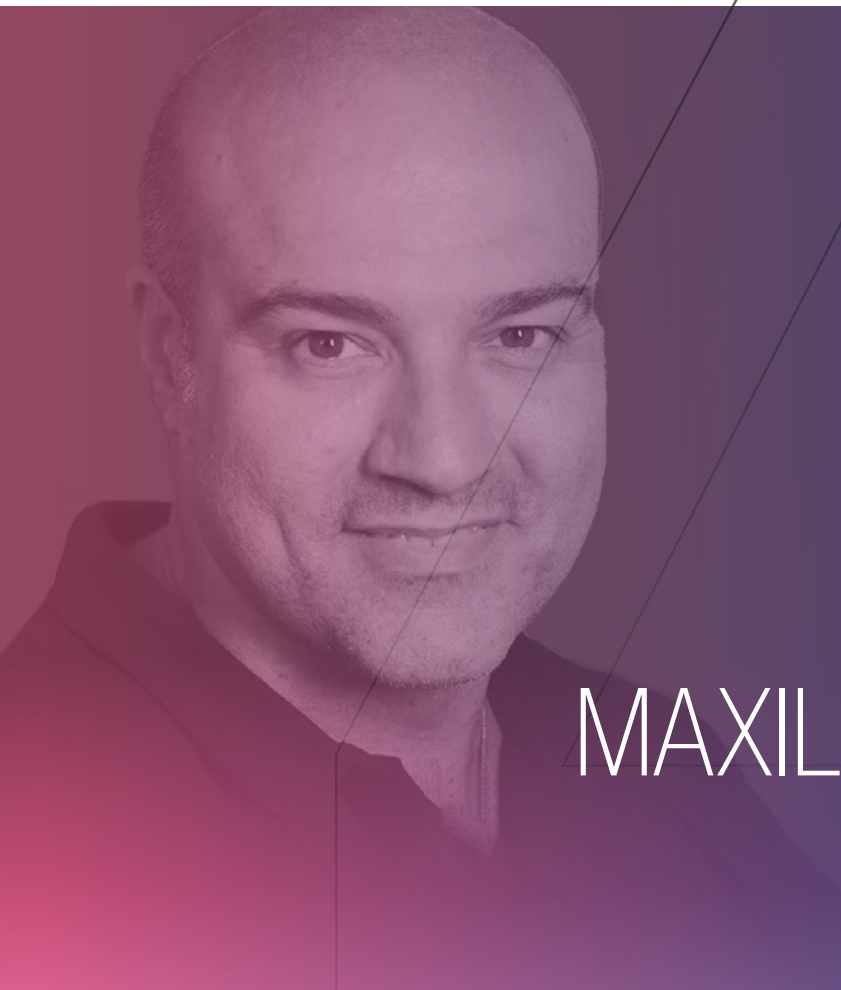
FIG. 07 The vestibular view showing natural-looking characterization.



RESTORATION OF A SINGLE MAXILLARY INCISOR

With **KATANA™ Zirconia STML**

Clinical Case by **Dr. Salvatore Scolavino**

The dental laboratory is confronted with the greatest aesthetic challenge whenever it comes to the restoration of a single incisor with natural adjacent teeth. In the following case, a young patient had undergone endodontic treatment of her maxillary left central incisor, while all other teeth showed their natural appearance. Tooth 21 (FDI notation) was due for replacement now.

To keep the natural identity, together with preserving the gingiva outline, the decision was taken in favour of a monolithic zirconia restoration. Using KATANA™ Zirconia STML (Kuraray Noritake Dental) with its four gradational layers from the cervical to the incisal area varying in chroma and translucency, it is possible to imitate the natural progression from yellowish to whitish-blue, and this in an easy manner. On the other hand, the zirconia irradiates into the gingiva and results in a natural looking shade all over the anterior area. For a lively and most natural-identical appeal, it was intended to individualize the crown with surface stains (CZR™ FC Paste Stain, Kuraray Noritake Dental Inc.).

Clinical Case 4

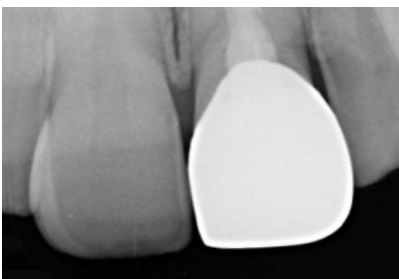


FIG. 01 X-Ray after endodontic treatment (with new crown on tooth 21 in place).

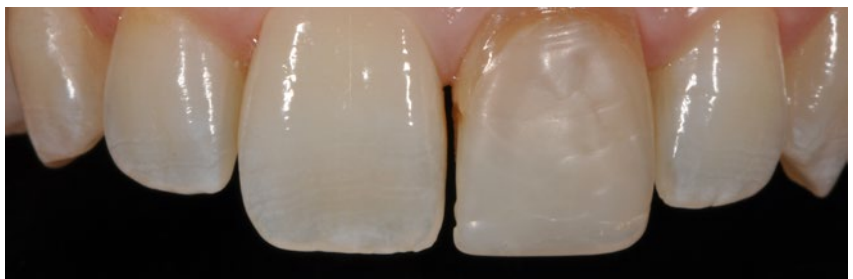

FIG. 02 The former restoration with which the patient showed up in the dentist's practice.

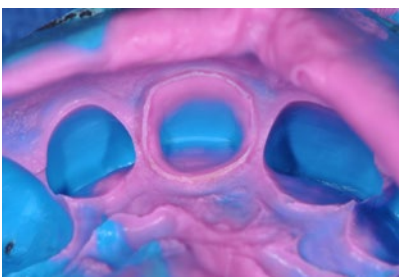

FIG. 03 Impression taken after tooth preparation.

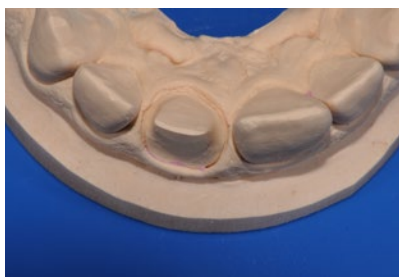

FIG. 04 Plaster model - the prosthetic baseline of the case. A careful analysis of the available space and the shape of the teeth allowed for a proper design of the planned crown.

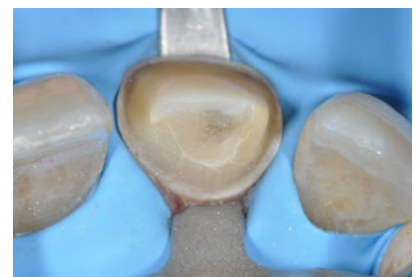

FIG. 05 Rubber dam placed for try-in of the zirconia crown.

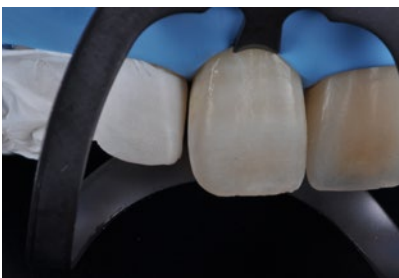


FIG. 06 Tooth 11 before recontouring the shape distally: This measure was planned to reestablish proximal contact points and harmonize the shape of both central incisors.

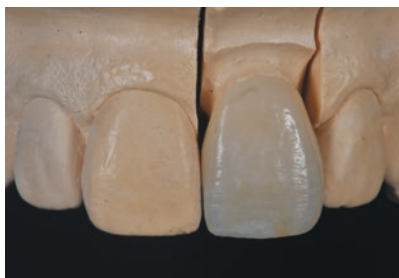

FIG. 07 Finished crown 21 on the plaster model. Notice: In order to match the shape of crown 21 and close-up the margins 11/12, composite has been added in the interproximal space.

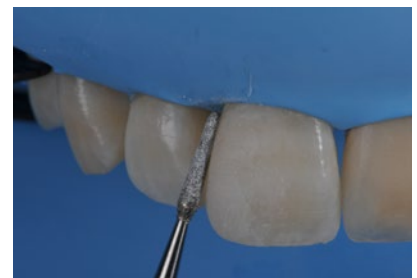

FIG. 08 Finishing the new distal outline of tooth 11 after extension with CLEARFIL MAJESTY™ ES Classic (Kuraray Noritake Dental Inc.) in the shade A2.

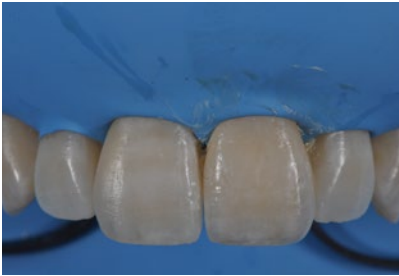

FIG. 9A Definitive placement of the restoration after the incorporation of an age-appropriate vestibular surface texture and surface staining.

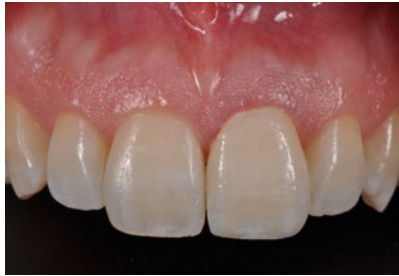

FIG. 9B Directly after placement.

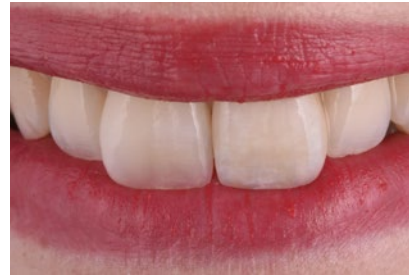

FIG. 9C View of the lips with the restoration in place.

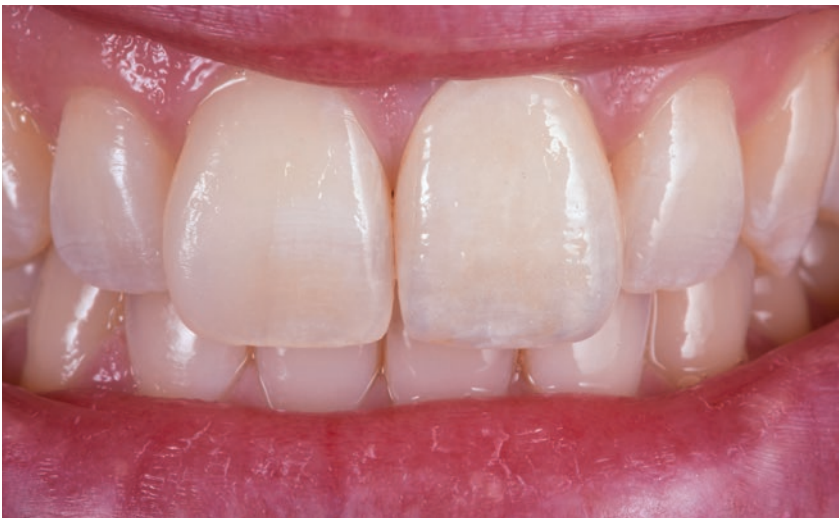

FIG. 9D Natural look of the upper and lower jaws.



UTML

THE EXPERT FOR ANTERIOR AESTHETICS

Recommended applications

- ✓ Veneers
- ✓ Inlays, onlays
- ✓ Anterior crowns

Additional applications

- ✓ Anterior up to premolar 2- or 3-unit bridges
- ✓ Single posterior crowns

Recommended finishing method

Monolithic design + ultra-micro-layering with CERABIEN™ ZR FC Paste Stain

Alternative finishing method

Vestibular cutback (0.3 mm) + micro-layering

	Minimum wall thickness	Minimum connector cross section
Veneer	0.4 mm	-
Anterior crown	0.8 mm	-
Inlay/onlay	1.0 mm	-
Posterior crown	1.0 mm	-
Anterior 2- or 3-unit bridges	0.8 mm	12 mm ²
Premolar 2- or 3-unit bridges	1.0 mm	16 mm ²

Translucency

51%

Flexural Strength

557 MPa

All light transmittance, illuminant: D65, Thickness of sample: 1.0 mm. White-color zirconia (base material) is used as testing material. Source: Kuraray Noritake Dental Inc.

Three point bending test according to ISO 6872:2015 - sample size 3 x 4 x 40 mm. Source: Kuraray Noritake Dental Inc.

Available disc thicknesses: 14 mm and 18 mm



ANTERIOR CROWNS ON TEETH AND IMPLANTS

With KATANA™ Zirconia UTML

Clinical Case by MDT Oriol de la Mata

Clinical Case 5

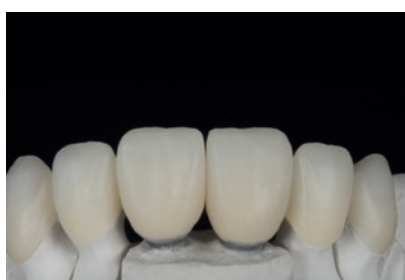


FIG. 01 Customized abutments on the model.

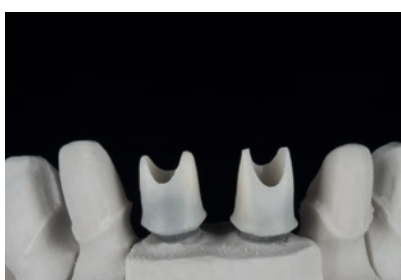

FIG. 02 Milled crowns before staining.

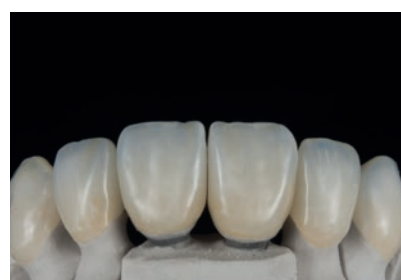

FIG. 03 Crowns after staining.

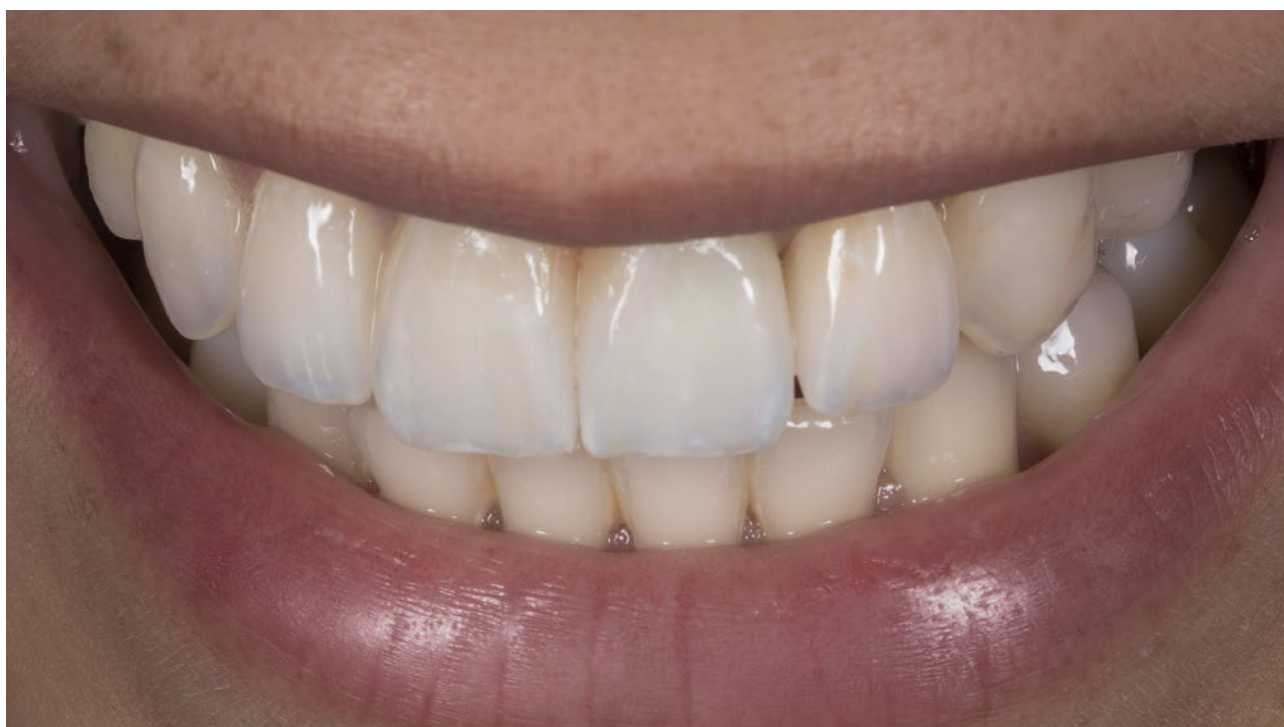

FIG. 04 Implant and tooth-based crowns in the patient's mouth.



HTML PLUS

THE SOLUTION FOR COMPLEX RESTORATIONS

Recommended applications

- ✓ Long-span bridges
- ✓ Frameworks in classical and cutback design

Additional applications

- ✓ Anterior crowns
- ✓ Posterior crowns
- ✓ Veneers

Recommended finishing method

Monolithic design + ultra-micro-layering with CERABIEN™ ZR FC Paste Stain.

Alternative finishing method

Vestibular cutback (0.3 mm) + micro-layering

	Minimum wall thickness	Minimum connector cross section
Veneer	0.4 mm	-
Anterior crown	0.4 mm	-
Inlay/onlay	0.5 mm	-
Posterior crown	0.5 mm	-
Anterior 2- or 3-unit bridges	0.4 mm	7 mm ²
Anterior 4-unit bridges or more	0.4 mm	9 mm ²
Posterior bridges	0.5 mm	9 mm ²

Translucency

45%

Flexural Strength

1,150 MPa

Measurement condition: Evaluated by base material (white color) All light transmittance, illuminant: D65, Thickness of sample: 1.0 mm

According to ISO 6872: 2015, Sample size: 3 x 4 x 40 mm
Data source: Kuraray Noritake Dental Inc. The numerical value varies according to a condition.

Available disc thicknesses: 14 mm, 18 mm and 22 mm

EFFICIENT PRODUCTION OF A ZIRCONIA OVERDENTURE

With **CERABIEN™ ZR**, **KATANA™**
Zirconia HTML Plus and **YML**

Clinical Case by CDT Mathias Berger

An elderly male patient with bruxism was in need of a new maxillary denture. Since the placement of five implants in the maxilla, he had no proprioception in this jaw. This lack of sensation had an impact on the overdenture to be produced: material and design needed to be carefully selected in a way that it would withstand uncontrolled chewing forces. As technical complications are easier to repair than biological complications, the overdenture should not be unbreakable – instead, the replacement of single units should be easily manageable.

The solution was a two-part design with a milled bar consisting of the gum area and tooth abutments combined with single crowns. The material of choice for the bar was KATANA™ Zirconia HTML Plus (Kuraray Noritake Dental Inc.) with a uniform flexural strength of 1,150 MPa throughout the disc, while the single crowns were milled from KATANA™ Zirconia YML that offers natural translucency and strength gradation. While a monolithic design was selected for the posterior crowns, the six crowns for the anterior region received a micro-cutback for aesthetic micro-layering with CERABIEN™ ZR Porcelain.

Clinical Case 6

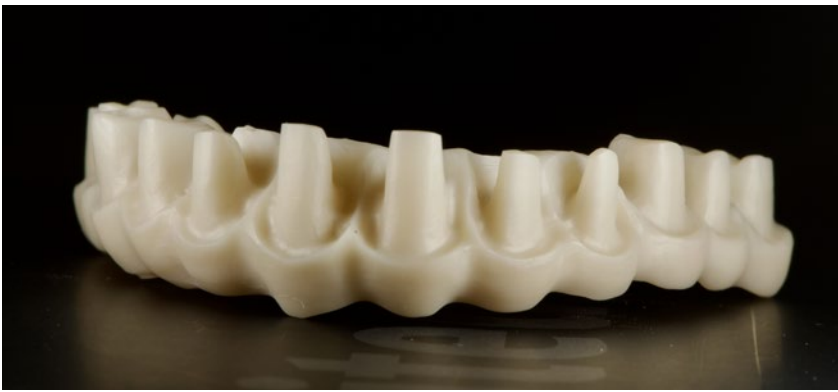

FIG. 01 Sintered bar milled from KATANA™ Zirconia HTML Plus..

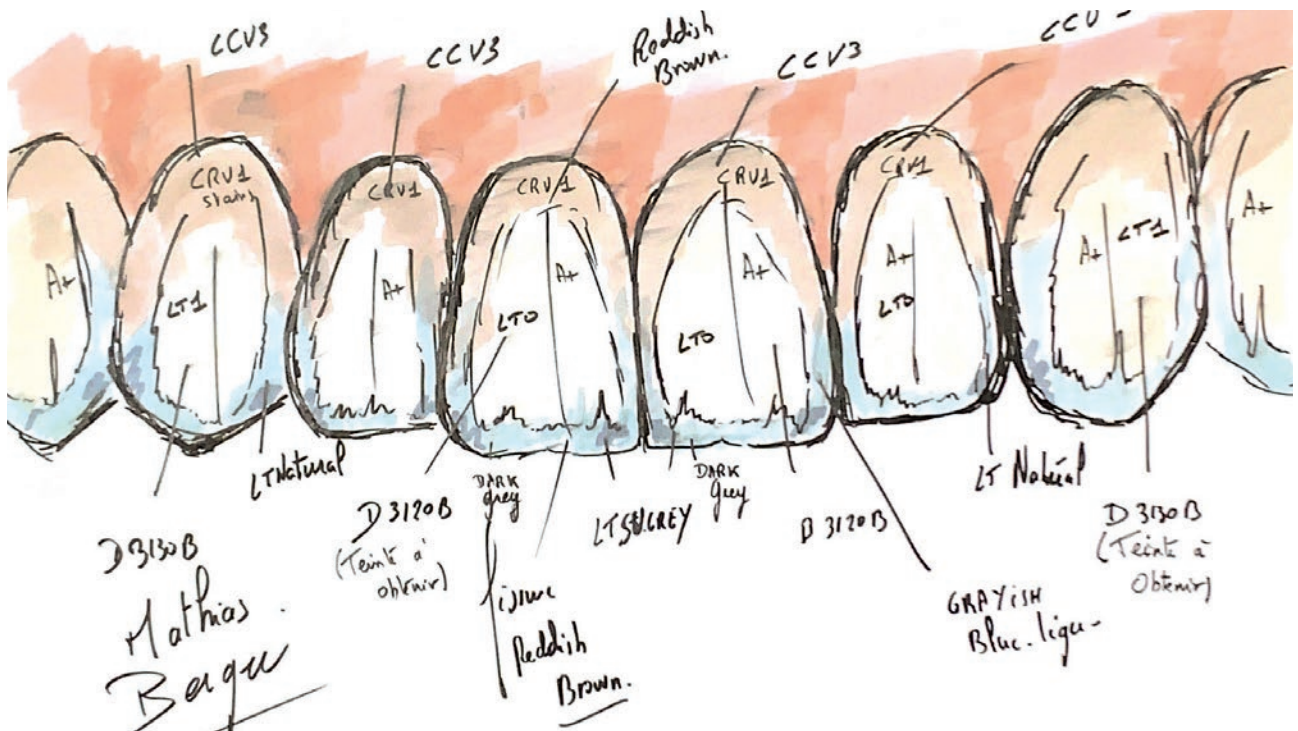


FIG. 02 Chroma map for micro-layering with CERABIEN™ ZR Porcelain in the anterior region.

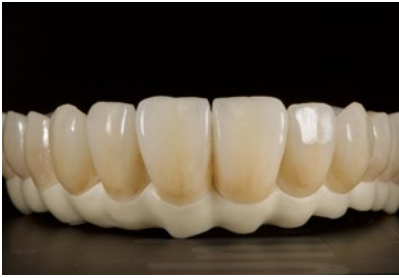

FIG. 03 Finished crowns on the sintered bar.

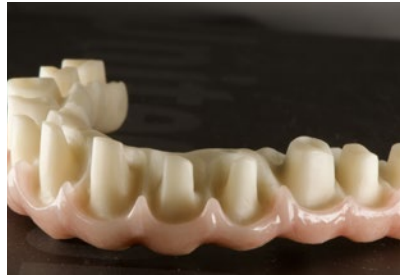

FIG. 04 Bar with gum areas individualized with CERABIEN™ ZR Tissue Porcelain.

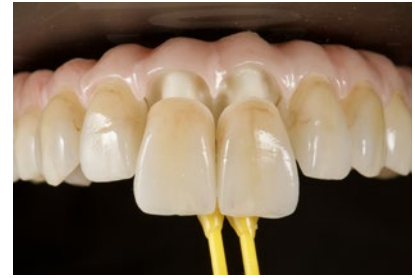

FIG. 05 Placement of the central incisor crowns on the bar.

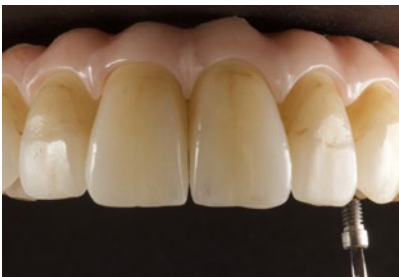

FIG. 06 Occlusal screw access hole in the finished overdenture (located in aesthetically uncritical positions).

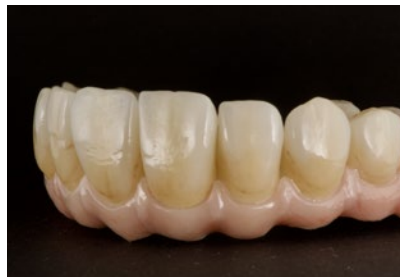


FIG. 07 Overdenture ready for try-in.

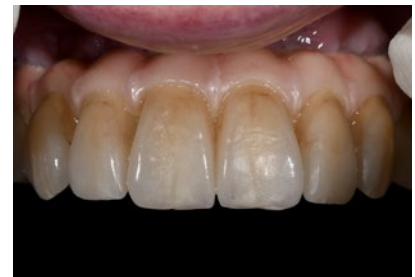

FIG. 08 Intraoral try-in of the aesthetic overdenture.

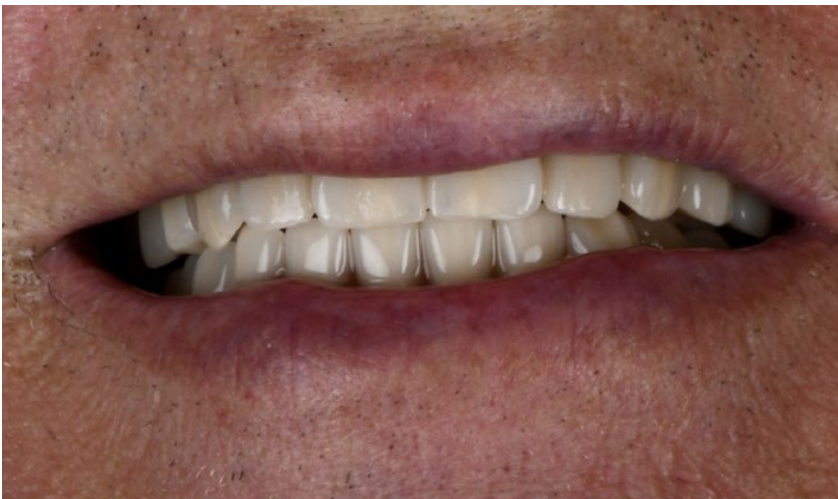

FIG. 09 Treatment outcome after fixing of the overdenture with screws and closing of the access holes with composite.



MONOLITHIC POSTERIOR CROWNS AND MICRO-LAYERED ANTERIOR CROWNS

With KATANA™ Zirconia HTML

Clinical Case by MDT Shigeru Adachi

Clinical Case 7

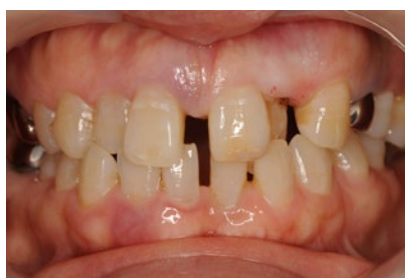

FIG. 01 Initial situation.

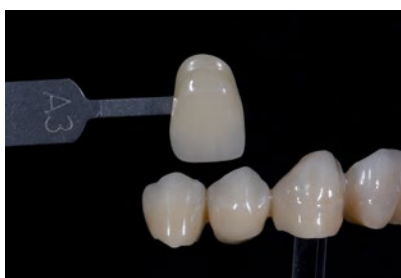


FIG. 02 Checking of the shade (posterior crowns: FC Paste Stain, anterior crowns: Micro-layered CERABIEN™ ZR).

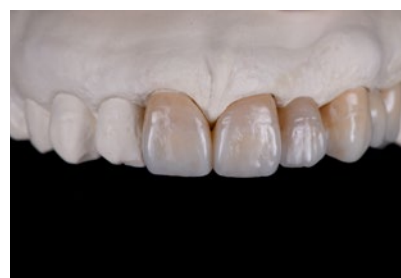

FIG. 03 Checking the restoration on the model.

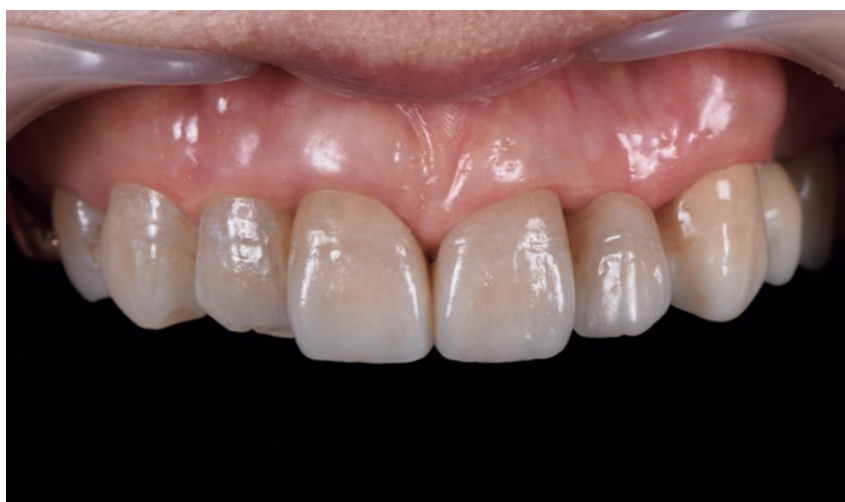

FIG. 04 Optical integration in the patient's mouth.



PRODUCTION OF A SCREW-RETAINED IMPLANT BRIDGE

With **KATANA™ Zirconia HTML** and **CERABIEN™ ZR**

Clinical Case by DT Pier Francesco Golfarell

KATANA™ HTML zirconia was selected, in consultation with the specialist, for its aesthetic and mechanical properties. One of our selection criteria was the advantageous lower abrasiveness level of zirconia compared to more traditional ceramics in combination with adequate mechanical polishing.

Clinical Case 8

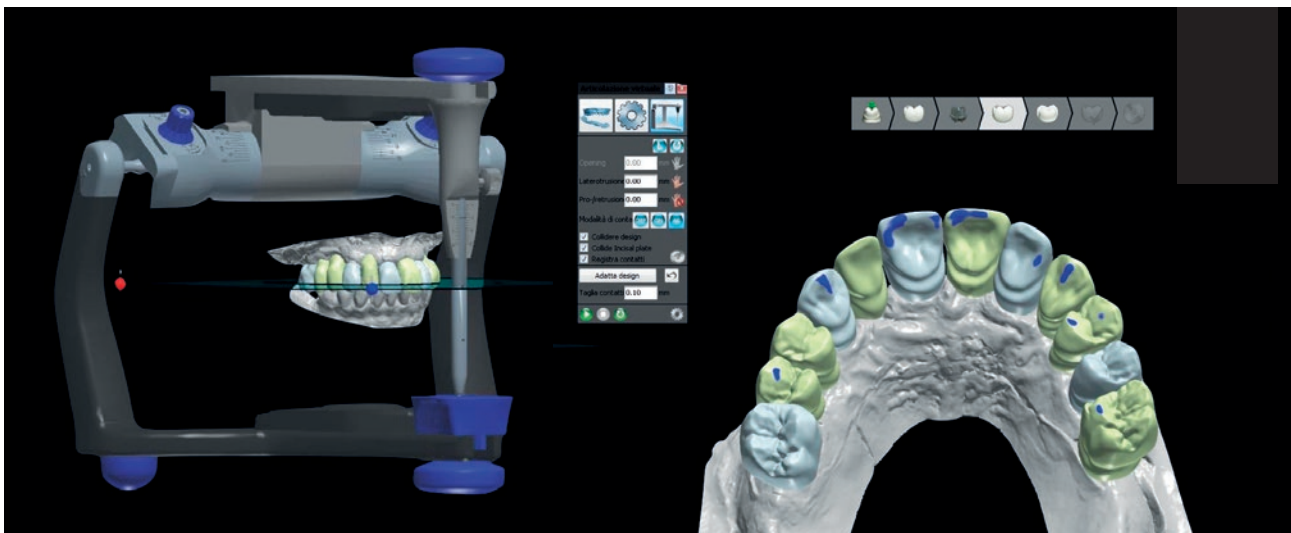


FIG. 01 CAD and articulation - 3Shape Dental Designer.

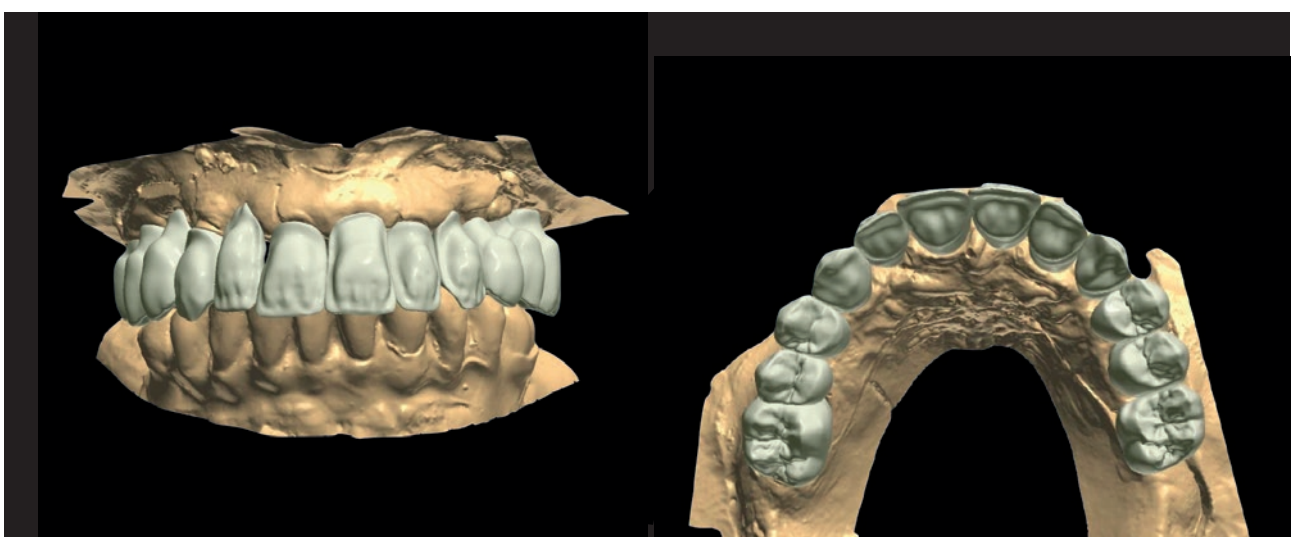


FIG. 01 Structure design with anterior cutbacks and a monolithic solution in the posterior area.

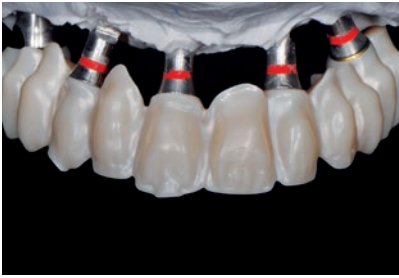

FIG. 03 KATANA™ Zirconia HTML structure.

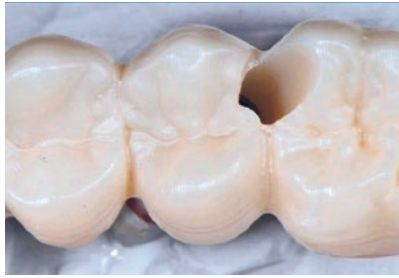

FIG. 04 Occlusal surface details.

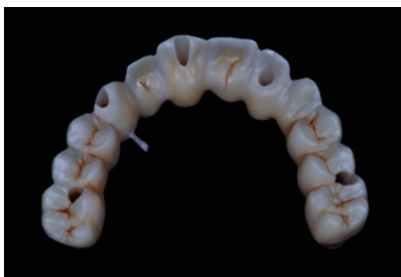
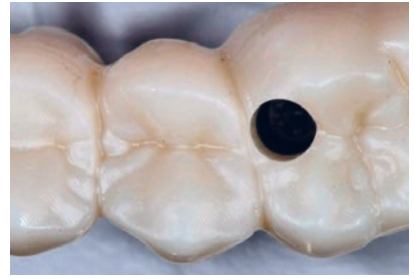
FIG. 05 CERABIEN™ ZR Shade Base Stain applied to the zirconia structure after sintering.

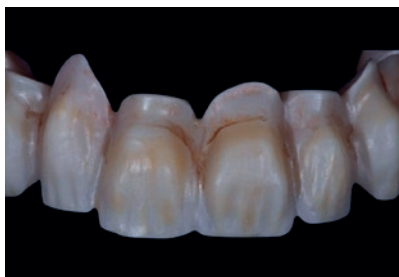

FIG. 06 Result of the shade staining procedure on the vestibular surfaces.

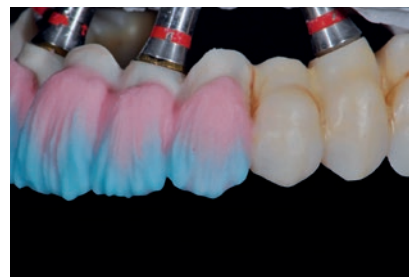

FIG. 07 Anterior layering according to the CORE & SHELL technique - creation of the core.

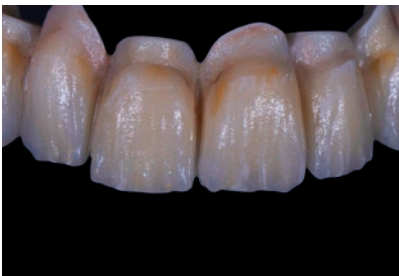

FIG. 08 Internal Live Stain (ILS) technique - application of internal stains.

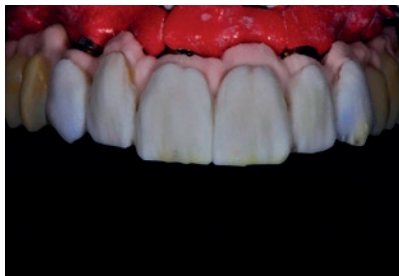



FIG. 09 Creation of the shell using luster porcelains.

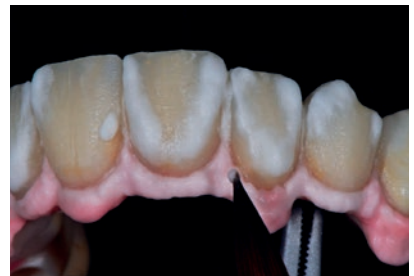

FIG. 10 Application of tissue porcelains to create the shell in the tissue area.

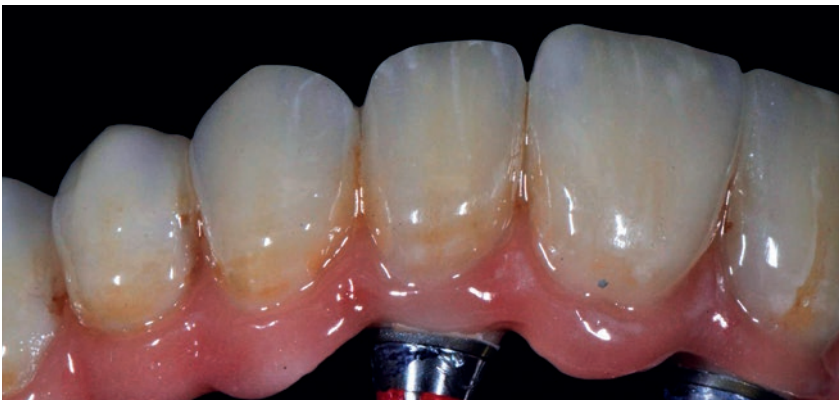

FIG. 11 Layering details.



FULL-MOUTH REHABILITATION USING MULTIPLE TYPES OF ZIRCONIA

With **KATANA™ Zirconia UTML, STML and HTML**

Clinical Case by Dr. Davide Cortellini and CDT Angelo Canale

This patient came to the clinic to improve her chewing ability and aesthetic level. The physical examination revealed the presence of several endogenous erosive lesions that made chewing difficult, in addition to partly affecting the aesthetics due to decrease in enamel thickness and the presence of dyschromic composite restorations. The possibility of using the new types of both tetragonal and cubic multilayer zirconia made it possible for us to plan the complete covering of all the elements with extremely conservative crowns with thicknesses between 0.5 and 1 mm in the axial and occlusal areas and up to 0.2 mm at the margin.

Clinical Case 9

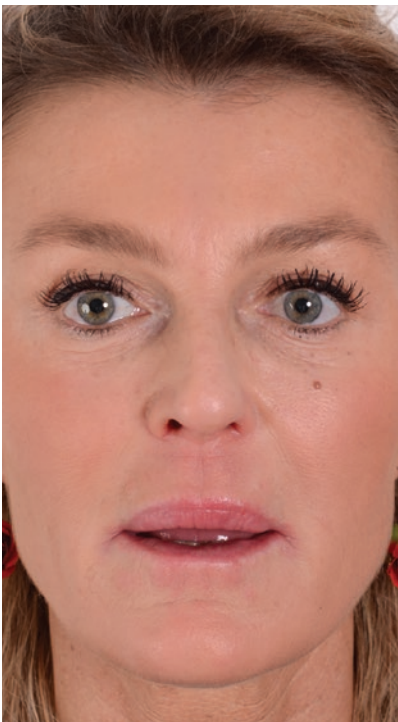

FIG. 1A Initial extraoral photographs




FIG. 1B ... and facial analysis ...



FIG. 1C ... used to plan the conservative full-mouth rehabilitation.

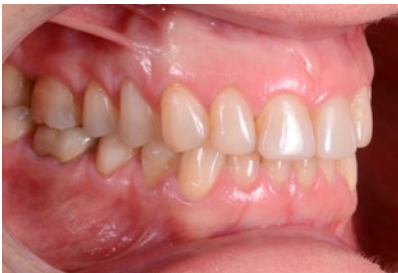

FIG. 2A Initial intraoral photographs: Lateral view from the right.

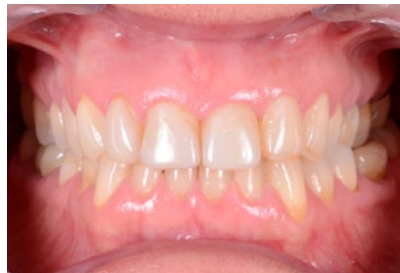

FIG. 2B Initial intraoral photographs: Frontal view.

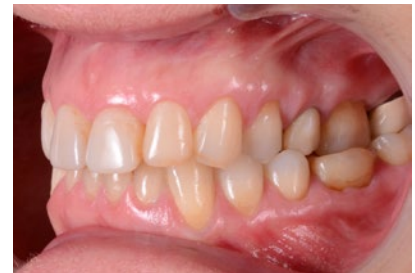

FIG. 2C Initial intraoral photographs: Lateral view from the left.

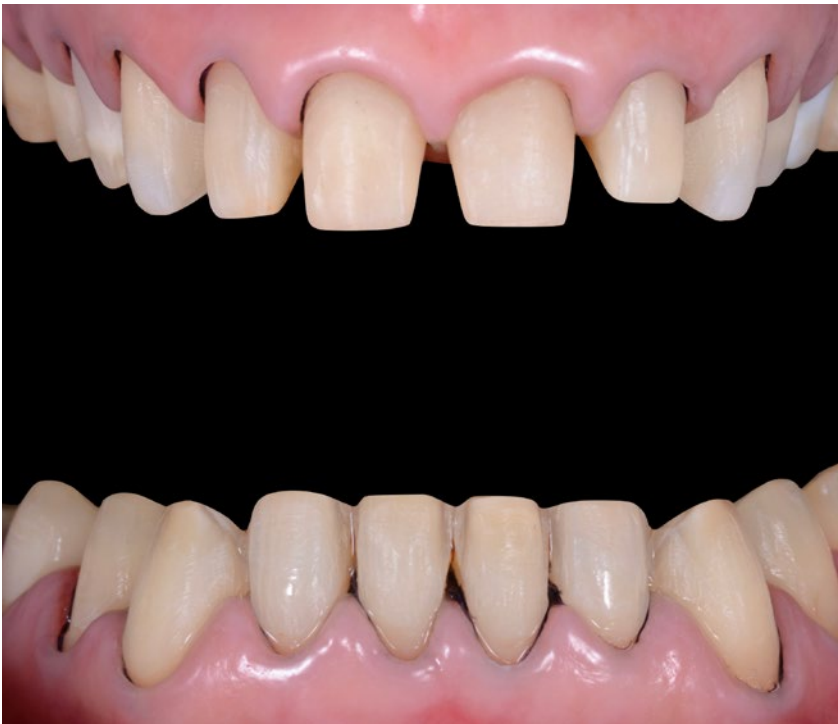

FIG. 3A Situation after very conservative vertical tooth preparation (knife edge preparation) without finishing line: Frontal view.

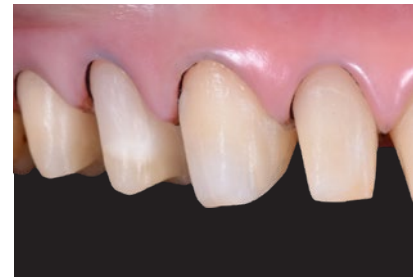

FIG. 3B Close-up view of the maxillary right quadrant.

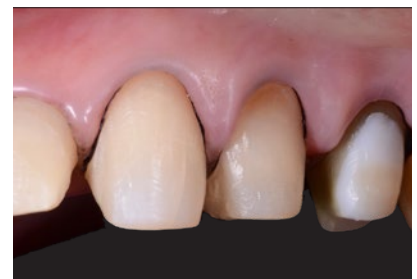

FIG. 3B Close-up view of the maxillary left quadrant.

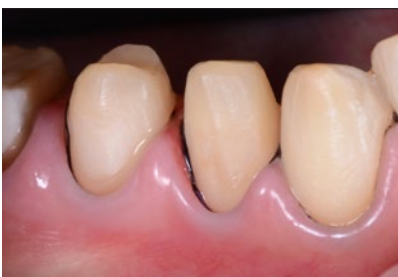

FIG. 3B Close-up view of the posterior teeth in the mandibular right quadrant.

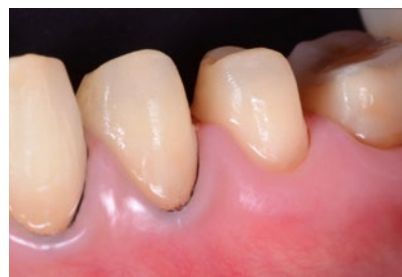

FIG. 3B Close-up view of the posterior teeth in the mandibular left quadrant.

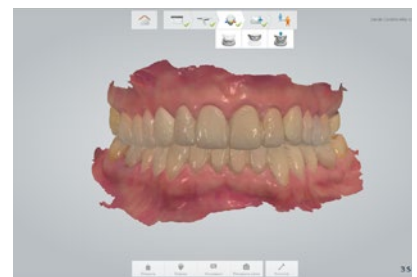

FIG. 4A Impressions taken with a 3Shape TRIOS intraoral scanner: scan of the temporary.

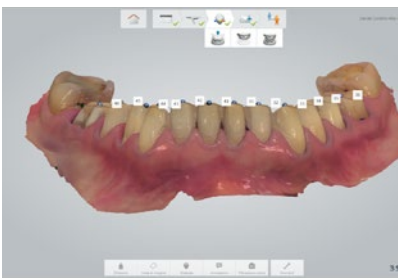

FIG. 4B Scan of the lower arch.

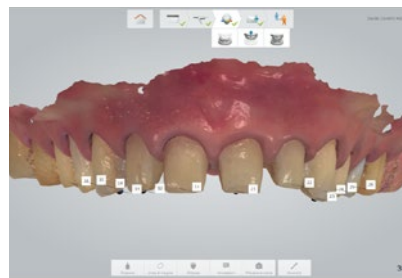

FIG. 4C Scan of the upper arch.

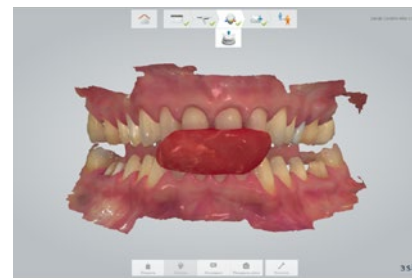

FIG. 4D Bite scan.

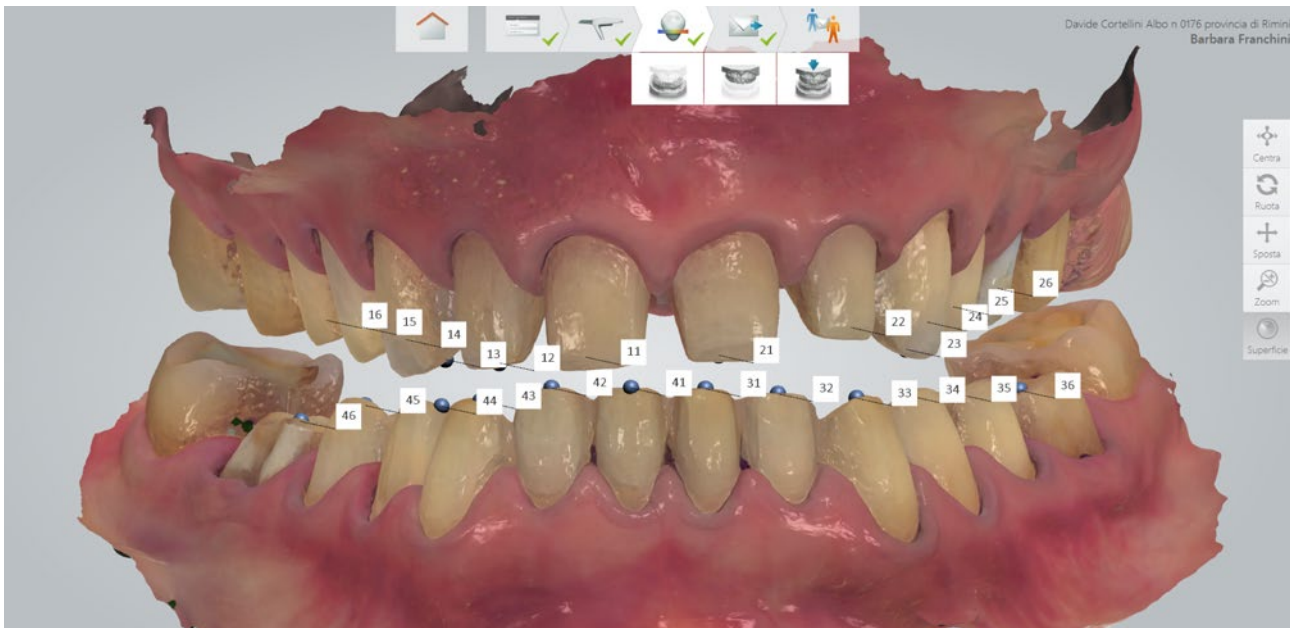


FIG. 4E Digital DV models of prepared teeth.

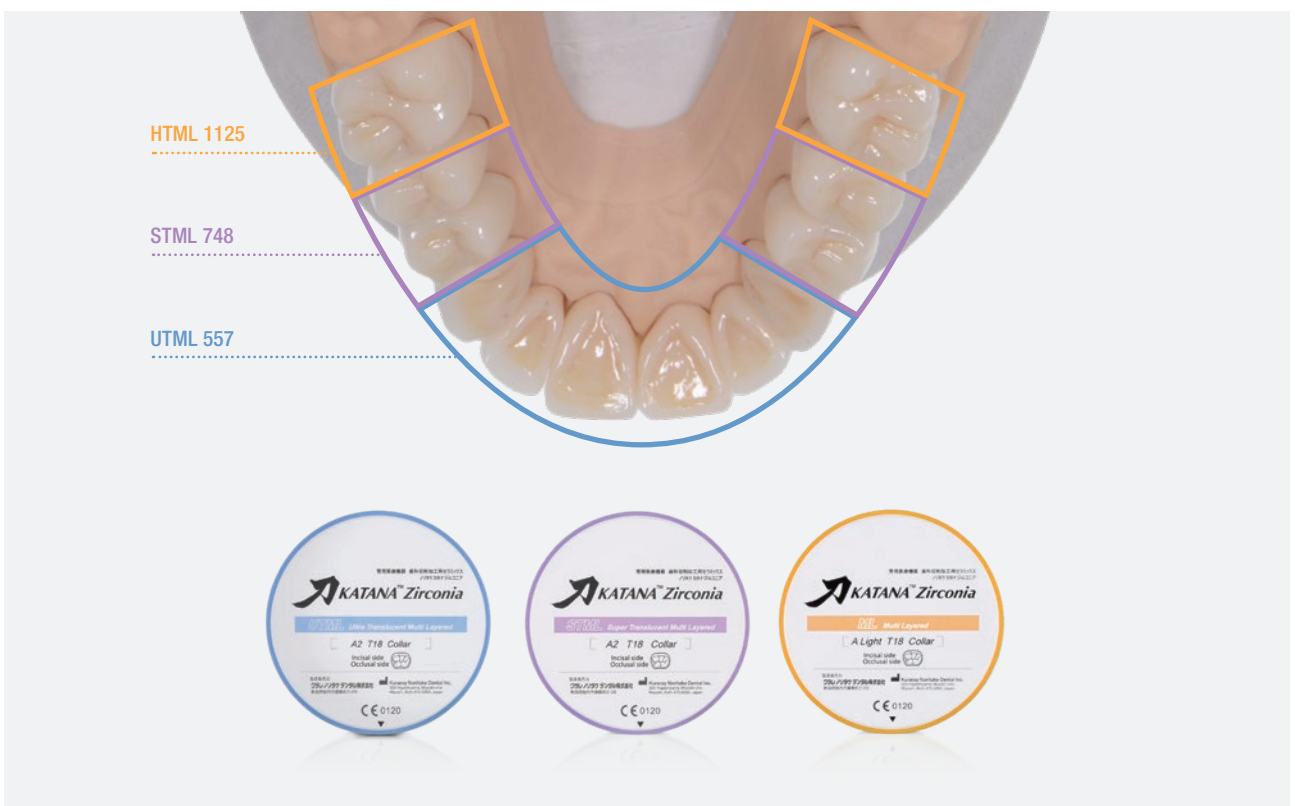

FIG. 05 The final restorations show excellent integration between the three different types of zirconia and a good natural feeling. The three different materials were selected on the basis of the specific positions inside the mouth:

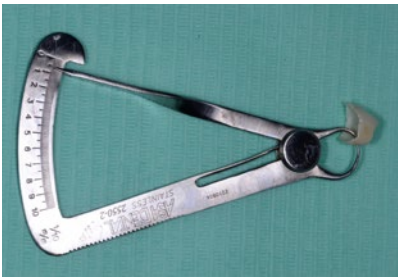

FIG. 6A Bucco-lingual thickness: 0.6 mm

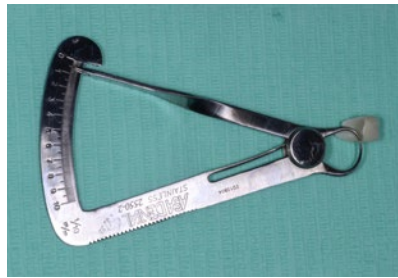

FIG. 6B Interproximal thickness: 0.5 mm

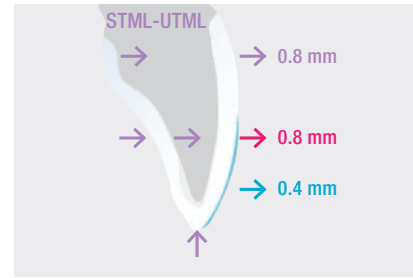


FIG. 7A MINIMAL PREP - minimal wall thickness of KATANA™ Zircona.

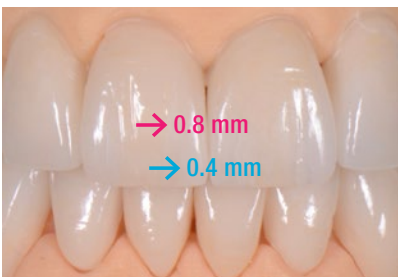

FIG. 7B Restorations with minimal wall thickness on the model.

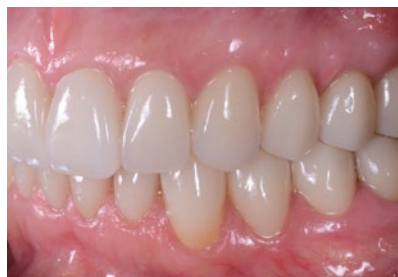

FIG. 8A Functional and beautiful treatment outcome: Lateral view from the left.

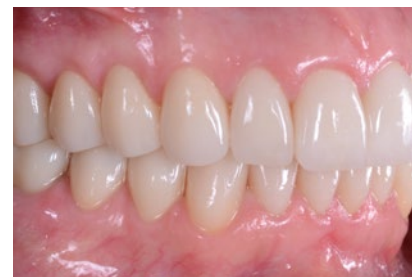

FIG. 8B Functional and beautiful treatment outcome: Lateral view from the right.

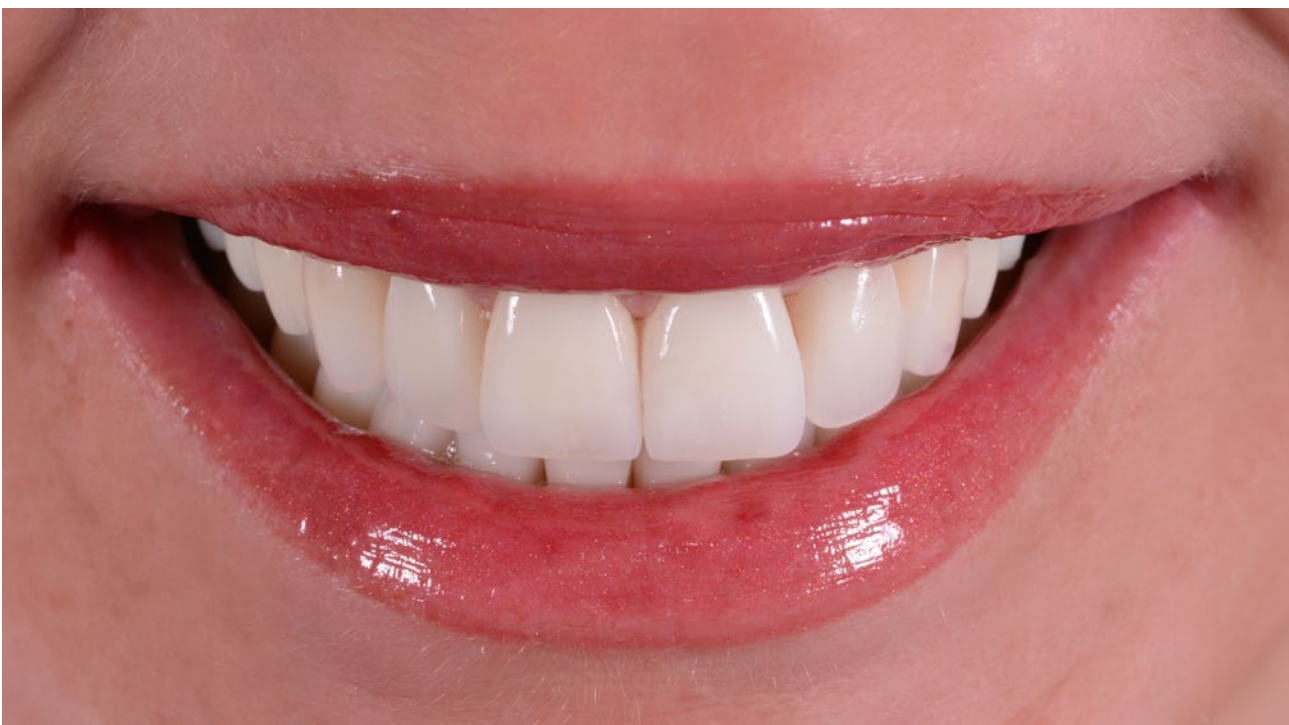

FIG. 8C The high translucency especially in the anterior region creates a true-to-life appearance.



DISCOVER KATANA™ Zirconia Discs



EU Importer

Kuraray Europe GmbH

Philipp-Reis-Strasse 4,
65795 Hattersheim am Main, Germany

Phone +49 (0)69 305 35 835

Fax +49 (0)69 305 98 35 835

www.kuraraynoritake.eu

centralmarketing@kuraray.com

- Before using this product, be sure to read the Instructions for Use supplied with the product.
- The specifications and appearance of the product are subject to change without notice.
- Printed color can be slightly different from actual color.

"KATANA" and "CERABIEN" are trademarks of NORITAKE CO., LIMITED.



Kuraray Noritake Dental Inc.

300 Higashiyama, Miyoshi-cho, Miyoshi, Aichi 470-0293, Japan



1639

